

# implants

international magazine of oral implantology

## research

Professional implant  
management

## case report

Combining standard  
and ultrashort implants in  
full-mouth rehabilitation

## case report

Interproximal root spreading  
for narrow implant placement





# Tissue Level Implants with Zirconia Collar



Digital workflow at  
your fingertips

Zirconia crown made by Index  
One milling machine

Aesthetic gingival area

Zirconia collar

Gingival integration  
& Osseointegration

Bone area

Pure Titanium body



Unique, like your smile

The Z1® implants are medical devices intended for placement in the mouth, in case of partial or total tooth loss, by qualified healthcare professionals. These medical devices are regulated health products which, in accordance with this regulation, bear the CE marking. These dental implants are manufactured in France by Sudimplant SAS, owner of the Z1® trademark. For any information, please contact your dentist.



Find us online  
[www.tbr.dental](http://www.tbr.dental)

**Dr Georg Bach**  
President of DGZI

**Dr Rolf Vollmer**  
First Vice President and Treasurer of DGZI



## To be continued . . .

Through the 3<sup>rd</sup> Future Congress for Dental Implantology, the German Association of Dental Implantology (DGZI) planned to celebrate its 50<sup>th</sup> anniversary this year in its founding city of Bremen. The outstanding congress concept, the streaming of live surgeries, the myriad of scientific lectures delivered by renowned speakers, the table clinics with hands-on character, the digital poster presentation and the now traditional get-together would have made for a truly extraordinary scientific event for continuing professional development. At the congress, attendees would have had the opportunity to reflect on half a century of oral implantology in Germany, which in its essence is deeply entwined with the work of DGZI. The objective was to highlight major current developments and to envision what implantology of the future could look like. The congress would have been the perfect platform for collegial exchange, discussions with experts and fruitful talks with industry representatives.

In the past months, a great deal of effort has been invested in the preparation of the congress. Time and again, attempts have been made to adapt the concept to the dynamically changing COVID-19-related restrictions on public gatherings and stipulations regarding hygiene measures. These unpredictable circumstances have made it increasingly difficult to realise an event of such magnitude and complex character. After all, personal exchange and close interaction between partic-

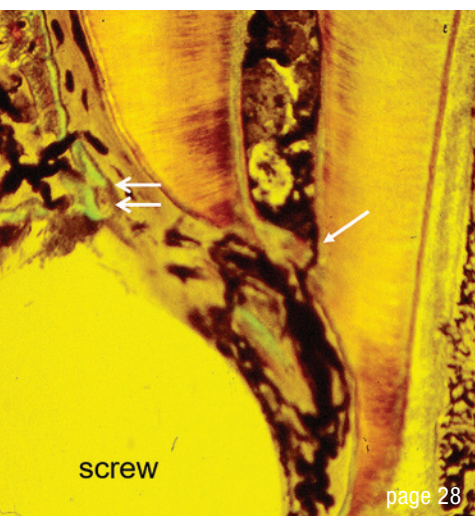
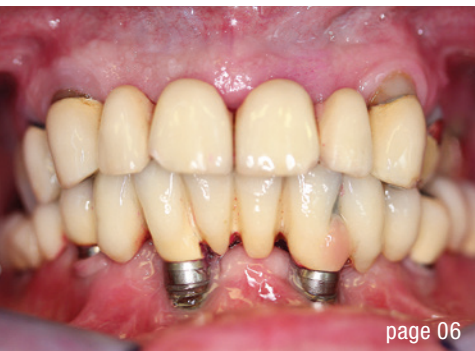ipants is the foundation that the Future Congress is based on. Additionally, the limited number of participants allowed in the city of Bremen at the time of writing would have meant that about half of the congress registrations would have had to have been cancelled. In view of the dramatically surging number of infections, there was little hope that the situation would change and hence, considering the importance of protecting the health of all those involved, DGZI ultimately had to reschedule the congress.

DGZI would like to take this opportunity and thank all participants, speakers, industry experts and the organiser, OEMUS MEDIA. Without their trust and committed support, this long-planned project would never have come so far. We invite you to follow the continuing efforts at DGZI, and we already look forward to welcoming you to the 3<sup>rd</sup> Future Congress for Dental Implantology—our 50<sup>th</sup> International Annual Congress—in 2021.

The fact that not everything has had to be subordinated to the pandemic is underlined by this year's fourth issue of *implants—international magazine of oral implantology*. We wish you and your entire practice staff an enlightening read, good health and mental resilience for the weeks and months to come.

Yours, Drs Georg Bach & Rolf Vollmer





Cover image courtesy of TBR Dental Group  
www.tbr.dental



## editorial

- To be **continued** ... 03  
Drs Georg Bach & Rolf Vollmer

## research

- Professional** implant management 06  
Marie-Therese Heberer & Prof. Nicole B. Arweiler
- SEM **investigation** of implant surface characteristics 14  
Drs Branislav Fatori & Inge Schmitz

## case report

- Mandibular **dentigerous** cyst 16  
Drs Fernando Duarte & Carina Ramos
- Combining **standard** and **ultrashort** implants in full-mouth rehabilitation 22  
Drs Giovanni Ghirlanda, Michele Vasina & Laura C. Campos
- Interproximal **root spreading** for narrow implant placement 28  
Dr Mauro Marincola, Dr Laura Murcko, Dr Giorgio Lombardo & Prof. Rolf Ewers
- Immediate **placement** of a new fully tapered tissue-level implant 32  
Dr Mario Rocuzzo

## practice management

- Practice **strategies** in the time of the coronavirus 34  
Dr Anna Maria Yiannikos

## news

- manufacturer news 36
- news 40

## about the publisher

- imprint 42





## NovoMatrix™ Reconstructive Tissue Matrix – the next generation material

NovoMatrix™ Reconstructive Tissue Matrix is an acellular dermal matrix derived from porcine tissue intended for soft tissue applications. The proprietary LifeCell™ tissue processing is designed to maintain the biomechanical integrity of the tissue, which is critical to support tissue regeneration.

### Indications

- Localized gingival augmentation to increase keratinized tissue (KT) around teeth and implants
- Alveolar ridge reconstruction for prosthetic treatment
- Guided tissue regeneration procedures in recession defects for root coverage

### Product features

- Consistent thickness (1 mm)
- Pre-hydrated
- Controlled source

[www.biohorizonscamlog.com](http://www.biohorizonscamlog.com)

# Professional implant management

## A balance between thorough but gentle cleaning

Marie-Therese Heberer & Prof. Nicole B. Arweiler, Germany

**The treatment of** peri-implant disease remains a great challenge for the practising dentist. In spite of current guidelines, a direct therapy recommendation for treating diseased implants is still lacking. Owing to demographic change and the wide range of indications for implants, peri-implant disease is becoming an increasingly relevant problem in everyday practice. Since peri-implantitis is an irreversible disease that can lead to pain, severe aesthetic impairments and implant loss, it is necessary to adequately care for implants and treat the first signs of peri-implant inflammation at an early stage.

### On peri-implantitis and how it can occur

Peri-implant health and disease were classified in the context of periodontal and peri-implant diseases and conditions at the joint World Workshop of the American Academy of Periodontology and the European Federation of Periodontology in 2017 for the first time.<sup>1</sup> Table 1 provides an overview of the case definition of peri-implant health and peri-implant disease. Peri-implant health, on the one hand, is clinically defined as the absence of signs of inflammation such as erythema, bleeding on probing, swelling and suppuration. Peri-implant diseases, on the other hand, are classified as biofilm-associated diseases that are clinically conspicuous by inflammatory changes in peri-implant soft tissue accompanied by bleeding on probing and/or suppuration.<sup>2</sup> Compared with measurements at the time of insertion of the superstructure (baseline), which are caused by progressive bone loss that goes beyond the initial remodelling, peri-implantitis shows increased probing depth.<sup>3</sup> Given the lack of radiographs and probing depth measurements at baseline (directly after superstructure insertion), radiographic ev-

idence of a bone level of  $\geq 3$  mm and/or a probing depth of  $\geq 6$  mm connected with heavy bleeding and/or suppuration after probing are sufficient for the diagnosis of peri-implantitis. In contrast, peri-implant mucositis does not involve any decrease of the crestal bone level beyond the initial remodelling after insertion of the implant.

Similar to periodontitis, which is almost always preceded by chronic gingivitis, peri-implant mucositis exists before peri-implantitis arises. As mentioned earlier, this is marked by signs of inflammation, but does not yet involve bone resorption. Peri-implant mucositis is strongly associated with biofilm, which makes it—fortunately—reversible by adequate biofilm management. The transition to peri-implantitis is fluid and cannot be diagnosed clearly, and this must be taken into account when selecting the treatment approach. The cause of the progression of peri-implant mucositis to peri-implantitis has not been identified yet,<sup>1</sup> but the risk factors described later certainly play a role. If no elaborated therapy for peri-implantitis is provided, rapid, often non-linear progression of bone resorption and inflammation occurs,<sup>4</sup> presumably with faster spread and higher prevalence than in periodontitis. Peri-implantitis can already occur at the beginning of the maintenance phase, even shortly after the implantation. Noticeable problems can be expected after five years, and 20 % of patients require peri-implantitis therapy after five to ten years.<sup>5</sup> Some experts report the start of the disease two to three years after implantation.<sup>6</sup>

### Risk factors for peri-implantitis

The aetiology of peri-implantitis is comparable to that of periodontitis. Both are multifactorial events that are modi-

	Peri-implant health	Peri-implant mucositis	Peri-implantitis
BOP and/or suppuration with gentle probing (possibly increased PD compared with baseline)	–	+	+
Bone loss	–	–	+

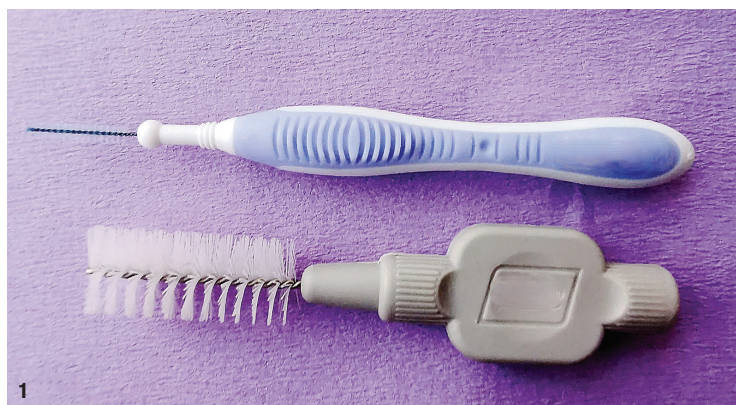
**Table 1:** Case definition of peri-implant health and disease according to the new classification.<sup>1</sup>

fied by co-factors multiple times. Bacterial (plaque) biofilm accumulation, which causes an initial immune response (inflammation), can be seen as the main cause. It is directly related to the oral hygiene of the patient. It is crucial to avoid restorations with difficult-to-clean niches—especially in older patients—which requires a close co-operation between dentist and dental technician.<sup>7</sup> Poor cleanability of the implant and its superstructure and thus biofilm accumulation as well as cement residue are termed as local modifying factors.

Patients who already have a severe form of periodontitis prior to implant placement, have poor biofilm control and are not integrated into a regular aftercare system (supportive periodontal therapy) can be classified as a high-risk group.<sup>8</sup> Patients with periodontitis have been shown to have a significantly higher rate of peri-implantitis occurrence within ten years (28.6 % vs 5.8 %) and thus a significantly lower success rate (71.4 % vs 94.5 %).<sup>9</sup> Therefore, healthy periodontal conditions through systematic periodontitis therapy and a high-frequency recall system must be guaranteed, even before implant placement.<sup>10</sup> In other words, only if both conditions are met is the patient ready for implants. Reducing the accumulation of bacteria immediately prior to implant placement is recommended, for example mucosal antisepsis with chlorhexidine rinsing solution. Subsequently, wound healing must be optimised.<sup>11</sup> In addition, smoking cessation should take place before implant placement.<sup>8, 12</sup> The development of peri-implantitis has thus far been considered to be particularly favoured by the combination of pre-existing periodontal disease and smoking.<sup>5, 13–15</sup> Diabetes mellitus and interleukin-1 polymorphism, especially, have been systemic risk factors so far.<sup>8, 16–18</sup> A recent paper evaluates excess cement as a potential risk factor/indicator, but states that data identifying “smoking” and “diabetes” as risk factors are so far inconclusive.<sup>4</sup>

## Differences in the inflammatory response

Whether the bacterial spectrum in peri-implantitis is different from that in periodontitis, which would also result in a slightly different immune response, is matter of much discussion. Implants of titanium or ceramic have a bio-compatible surface, but no biological surface. For osseointegration, they should have a large-volume, sponge-like surface. However, these surfaces, if they are exposed or become accessible to bacteria, offer perfect conditions for bacterial proliferation. A Swiss research group compared the inflammatory reaction to 21 days of plaque accumulation on the tooth and implant in an experimental gingivitis/mucositis model using plaque and bleeding indices and inflammatory markers.<sup>19</sup> While no significant differences in plaque index between tooth and implant were revealed, significant differences were found for the gingival index and inflammatory markers (active matrix metalloproteinase-8 and interleukin-1 $\beta$ ). Both were sig-



**Fig. 1:** Interdental brushes have to be selected individually—even for implants. The fitting should be part of the instruction during prophylaxis sessions.

nificantly higher for implants than for teeth despite very similar plaque accumulation. This is probably due to the lack of a periodontal ligament on implants.<sup>19</sup>

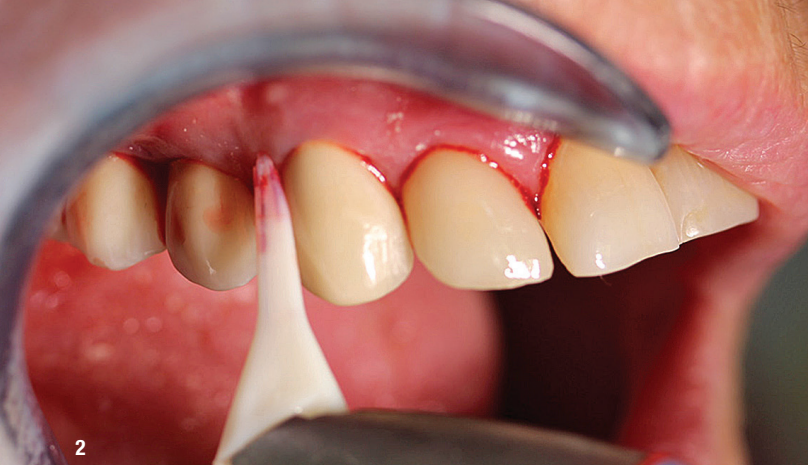## On peri-implantitis prophylaxis

The most important pillar should be the avoidance of peri-implant disease. Problematically, just as with periodontitis, peri-implant disease is rarely conspicuous at the initial inspection, is largely painless and shows few symptoms. For this reason, the patient is not able to make a self-diagnosis, which often leads to a delayed diagnosis and, in particular, a significantly late start of therapy. The irreversibility of tissue loss explains the poor prognosis. For this reason, dentists and prophylaxis staff must prioritise precaution, that is, optimum maintenance care of the inserted implant and its superstructure. Prophylaxis for the implant does not only mean prophylaxis sessions every three to six months but also optimal instruction and motivation for good oral hygiene at home for the whole year.<sup>12</sup>

### Home care prophylaxis measures

Motivating patients by staining the teeth with a plaque disclosing agent is a proven method. This enables the dentist to specifically show the patient where an improvement in home biofilm management is necessary. The use of interdental brushes and the explanation of their application should be strongly recommended here (Fig. 1). Alternatively, soft picks are offered on the market. These are quite practical and usually cheaper, but the scientific data for an equivalence to interdental brushes is not yet available. In addition to mechanical biofilm control at home, chemical biofilm management can support measurements—especially for patients who cannot perform adequate cleaning of their implants.<sup>20</sup> This S3 level guideline<sup>20</sup> on “home care, chemical biofilm management” highlighted patients with implants and implant-supported dentures as those with a particularly high risk of inflammatory changes (gingivitis or mucositis). While 0.1–0.2 % chlorhexidine digluconate solutions are recommended





**Fig. 2:** Powder air polishing systems with low-abrasive powder (glycine and erythritol powder) clean gently.

for short-term (14-day) intensive bacterial reduction and therewith reduction of an acute inflammatory event, mouthrinses containing 0.06 % chlorhexidine, a special formulation of essential oils, a formulation with amine fluoride or stannous fluoride, or a formulation with cetylpyridinium chloride can support insufficient mechanical oral hygiene for a variety of reasons. For implants, the specific application of a 1 % chlorhexidine gel is also suitable. Regular professional mechanical biofilm removal by trained persons as well as an improvement of biofilm management at home are the basis for the success of the therapy, both for prevention and in the case of already existing peri-implantitis.<sup>7, 17, 21–23</sup>

#### Professional prophylactic measures

In addition to these prophylactic measures, the practitioner must identify the systemic and local risk factors already mentioned and at least provide the impetus to remove them, which should be done before implant placement if possible.<sup>8, 17</sup> In order to confirm success, but also to be able to recognise the necessity of further therapy measures, regular check-ups including measurements are also indispensable for the dentist throughout the patient's life. Measurements, supragingival and, where necessary, subgingival cleaning (scaling and root planing) should be performed up to four times a year and should be carried out at regular intervals. Checking the complete periodontal status is recommended at least once a year in the case of six-monthly follow-up intervals and at least twice a year in the case of three-monthly intervals.

#### Designing supportive peri-implant therapy

Good oral hygiene of the patient as well as regular, life-long maintenance care sessions at intervals of three to six months are the key to long-term success. The regular recording of findings in order to determine both the oral hygiene status and the attachment level to implants and to diagnose changes at an early stage are the basis for this. Part of each session of supportive peri-implant therapy should include supragingival measures as well as regular motivation and instruction of the patient on good home biofilm management. An essential part of these maintenance sessions should, if necessary, be devoted to subgingival instrumentation of the implants. Necessary

cleaning must not be omitted owing to fears of possible surface damage. A compromise must be found between protecting the implant by gentle instrumentation to avoid deep scratches on its surface and thorough cleaning. Rough implant surfaces show not only more biofilm but also a more pathogenic flora, whereas surfaces that are too smooth disrupt soft-tissue attachment and fibroblast attachment. Hence, a good balance between bacterial adhesion and soft-tissue adhesion must be found.<sup>23</sup> The practitioner has various therapy options for subgingival cleaning. Recently, Schmidt et al. conducted a series of studies to examine cleaning options for their balance between bacterial adhesion and soft-tissue adhesion.<sup>24–26</sup> The following conclusions were drawn:

- a) If curetting is necessary (i.e. radiographically visible deposits), titanium curettes should be used instead of the conventional steel curettes, as they are much gentler on titanium surfaces.
- b) Ultrasonic instruments with a plastic coating hardly change the surface roughness, but should be reserved for the removal of hard deposits.
- c) Air-powder prophylaxis units with low-abrasive powder (glycine and erythritol powder; air polishing) are ideal for biofilm removal. At probing depths of up to 5 mm, it is even possible to blast into the sulci. At higher probing depths, nozzle attachments should be used (Fig. 2). The spray jet of the nozzles is deflected laterally so that it does not radiate apically and the risk of emphysema formation is avoided.

The mentioned approaches (titanium curettes, ultrasonic instruments, air polishing with low-abrasive powder) are gentle on the implant surfaces, show good clinical results and do not differ significantly from each other. Steel curettes lead to greater surface roughness and should therefore be avoided.<sup>24–26</sup> Considering teeth, the clinical and microbiological results of subgingival air polishing for moderately deep pockets are similar to those of ultrasonic treatment.<sup>27</sup> Compared with conventional scaling and root planing, subgingival air polishing actually performs better in terms of its effectiveness in subgingival biofilm removal.<sup>28</sup> Good results for subgingival therapy with air polishing have also been demonstrated for implants with peri-implant disease.<sup>8</sup>

The effectiveness of hand instruments, adjuvant air polishing (glycine powder) and ultrasonic scalers has been proved by clinical studies on implants with a significant improvement in clinical parameters (especially bleeding on probing).<sup>29, 30</sup> The elimination of inflammatory signs should be the primary goal of all procedures.<sup>17, 31</sup> In addition to cleaning, an individual risk analysis and, if possible, the elimination of risks must also be part of maintenance care if they have developed after implant placement. This includes advice on quitting smoking but also an exchange with the attending physician or internist to optimise the control of any diabetes that may be present. Subgingival

*copa*  
**SKY**   
IMPLANT SYSTEM

The innovative hybrid connection  
for sophisticated restorations!



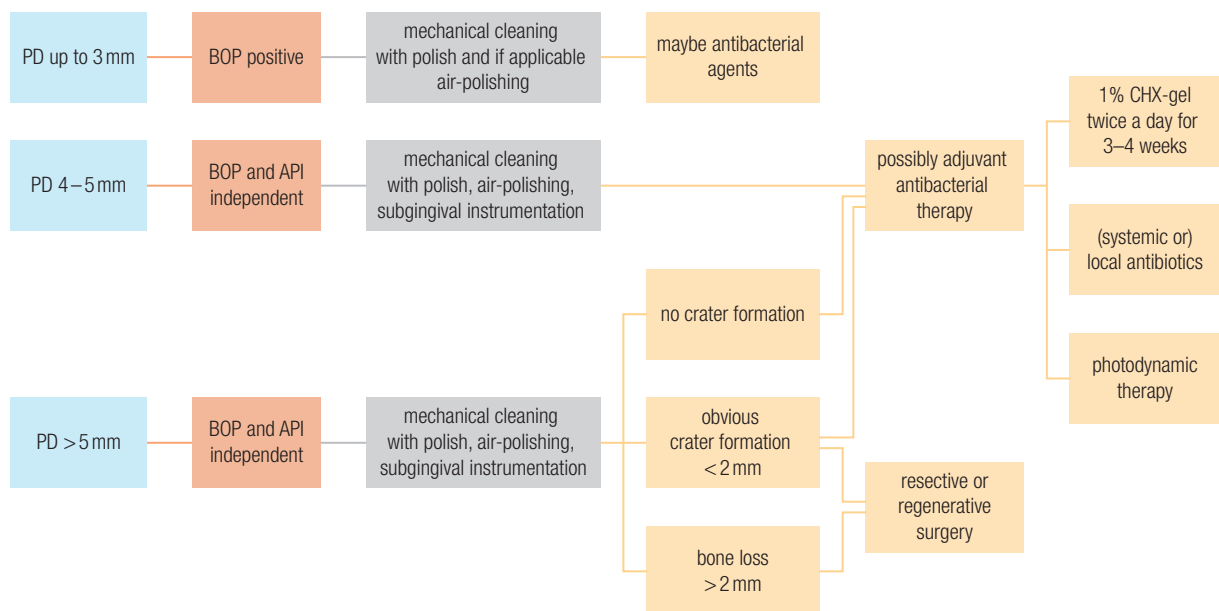
Conical?  
Parallel?  
  
The new  
copaSKY!

For subcrestal position | Unique prosthetic diversity | More space for the gingiva

DENTAL INNOVATIONS  
SINCE 1974

bredent<sup>group</sup>

bredent medical GmbH & Co. KG · Weissenhorner Str. 2 · 89250 Senden · Germany · T: +49 7309 872-441 · F: +49 7309 872-444 · [www.bredent-medical.com](http://www.bredent-medical.com) · @: [info-medical@bredent.com](mailto:info-medical@bredent.com)



**Fig. 3:** Therapy options for peri-implantitis therapy. PD = probing depth; BOP = bleeding on probing; API = approximal plaque index.

cleaning can also be supplemented in the context of a re-evaluation or supportive peri-implant therapy by antibacterial therapy measures such as local antibiotics, photodynamic therapy and laser as part of re-evaluation.

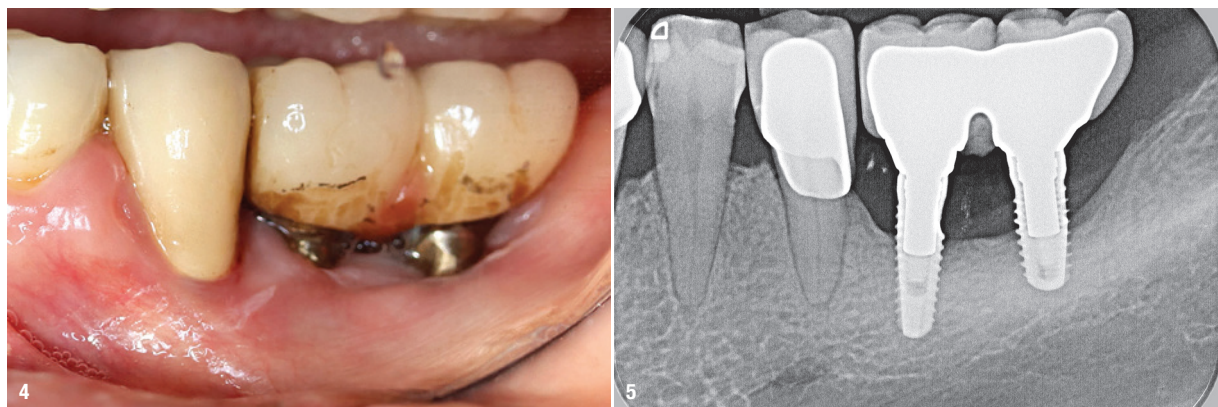
### What if peri-implantitis occurs nevertheless?

There is no standardised therapy scheme for peri-implantitis, but there are therapy suggestions that can be used to decide on the further course of action on an individual basis. These are shown in Figure 3 by a decision tree and are briefly explained in the following.

#### Non-surgical therapy for implants

The non-surgical removal of biofilm is the basis for any therapeutic approach to peri-implant disease and in the case of peri-implant mucositis in particular. For peri-implantitis therapy, the non-surgical approach is the important basic therapy and can be supplemented by further measures.<sup>17,32</sup> Nevertheless, the success in pockets

with an initial depth of > 7 mm is considered to be low.<sup>17</sup> In addition to an antiseptic home therapy to accompany biofilm control with chlorhexidine digluconate, it can be used as a complement to local mechanical debridement as pocket irrigation or as an application in gel form, which should lead to a significant improvement in probing depth after a control period of three or eight months. However, bleeding on probing is not affected by the use of chlorhexidine.<sup>33,34</sup> Further antibacterial procedures are, as mentioned before, local antibiotic therapy and photodynamic disinfection.<sup>12</sup> Significant reductions in probing depth, recession and plaque in cases of initial peri-implantitis have been proved for both local antibiotic therapy and photodynamic therapy (–0.15 mm).<sup>35</sup> For systemic antibiotic administration, no improvement in clinical and microbiological parameters has been found.<sup>36</sup> Figures 4 and 5 show a heavy smoker with moderate oral hygiene who—with exclusively non-surgical therapy measures—could be kept stable as far as possible because professional intervention was carried out early on. An elimination of the



**Fig. 4:** In this peri-implantitis patient (heavy smoker, moderate oral hygiene), small successes could be achieved through early scaling and root planing, and thus the situation was kept largely stable. Nevertheless, smoking cessation and an improvement in oral hygiene should be aimed for in order to achieve greater success. **Fig. 5:** Radiographic image of the same patient as in Figure 4.





# Guided Tissue & Bone Regeneration



## CERASORB® M

Resorbable, pure-phase  $\beta$ -tricalcium phosphate



## CERASORB® Paste

Resorbable  $\beta$ -tricalcium phosphate paste + hyaluronic acid matrix



## CERASORB® Foam

Resorbable  $\beta$ -tricalcium phosphate + collagen matrix



## Inion®

Resorbable pin fixation system



## Osgide®

Resorbable polylactic acid (PLA) membrane



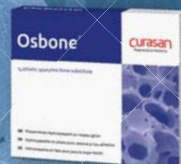## Epi-Guide®

Resorbable polylactic acid (PLA) membrane



## Ti-System

System for fixation of foils and membranes



## Osbone®

Synthetic spongius bone substitute



## Stypro®

Resorbable hemostyptic



## Tefguide®

Non-resorbable PTFE membrane

# One toolbox for your needs!

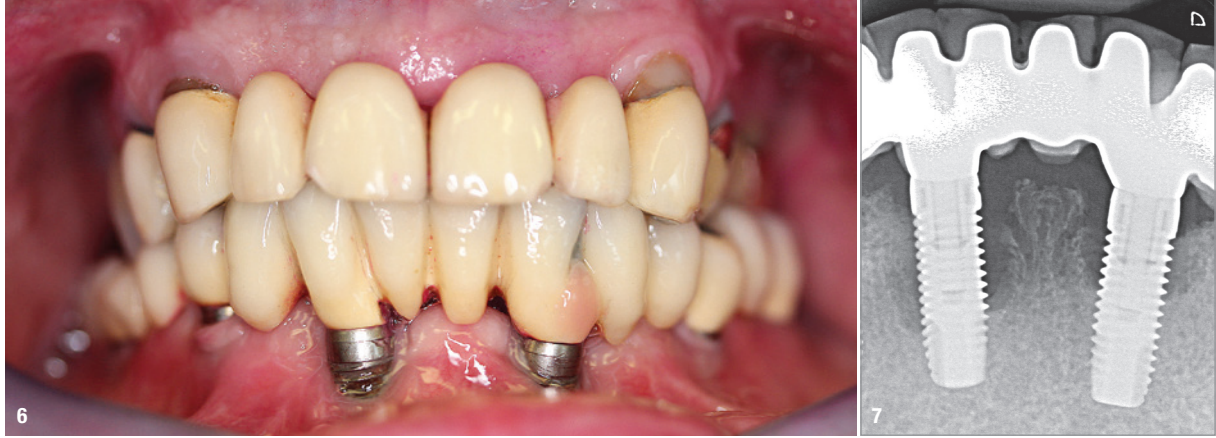# curasan

Regenerative Medicine

Phone: +49 6027 / 40 900-0

[info@curasan.com](mailto:info@curasan.com)

[www.curasan.com](http://www.curasan.com)



**Fig. 6:** Patient with severe advanced peri-implantitis whose superstructures in regions #32 and 42 were difficult to clean, but with satisfactory oral hygiene.  
**Fig. 7:** Radiographic image of the same patient as in Figure 6. The bowl-shaped bone resorption around the implants is clearly visible.

Defect type	Surgical technique
Deep bowl-shaped defect	<ul style="list-style-type: none"> <li>– Thorough cleaning and disinfection of the implant surface</li> <li>– Defect reconstruction</li> </ul>
No clear bone wall or significant horizontal bone resorption	<ul style="list-style-type: none"> <li>– Thorough cleaning</li> <li>– Reduction of the marginal mucosa with the aim of enabling effective oral hygiene by the patient</li> </ul>

**Table 2:** Selection of the surgical approach based on the bone defect (modified from Schwarz et al.<sup>21</sup> and Renvert & Polyzois<sup>39</sup>).

above-mentioned risk factors should be striven for in order to further improve the situation around the implants.

### Surgical therapy for implants


If peri-implantitis has progressed to such an extent that these conservative approaches with scaling and root planing no longer allow inflammation control and no improvement can be achieved (Figs. 6 & 7), resective or regenerative surgery or, in the worst case, explantation must be considered. When an implant has become loosened, explantation is the only therapy option.<sup>17</sup> The surgical technique should be selected based upon the bony lesion (Table 2). A recommendation for the exact technique cannot be given at this stage.<sup>17</sup> Studies however show a correlation between the success of regenerative therapy and the defect configuration.<sup>37</sup> Similar to a non-surgical approach, debridement and cleaning of the implant surface are the goals of the surgical procedure, which should be supplemented by defect reconstruction, reduction of probing depth and improvement of hygiene capability.<sup>31,32</sup> Additional surface decontamination with, for example, a 980nm diode laser does not show any improvement in the clinical or radiographic outcome of implants.<sup>17</sup> Unfortunately, as numerous publications emphasise, aesthetic losses must be accepted to prevent the progression of peri-implantitis.

### Summary

While a definitive concrete therapy recommendation for peri-implantitis therapy cannot be given at present, professional biofilm management in the practice as well as oral hygiene at home are the basis for the resolution of inflammation around the implant (as well as the tooth) and must therefore be practised regularly and well taught. Supplementary therapeutic measures such as local antibiotics,

photodynamic therapy and surgical approaches are possible and should be carried out depending on the degree of progression of the disease. Measures that significantly change the implant surface, such as the use of steel curettes or implantoplasty, should be avoided if possible.

*All images: © Marie-Therese Heberer & Nicole B. Arweiler*



### contact



#### Marie-Therese Heberer

Department of Periodontology and  
 Peri-Implant Diseases  
 Philipps University of Marburg, UKGM  
 Georg-Voigt-Straße 3  
 35039 Marburg  
 Germany  
 heberer@med.uni-marburg.de



#### Prof. Nicole B. Arweiler

Department of Periodontology and  
 Peri-Implant Diseases  
 Philipps University of Marburg, UKGM  
 Georg-Voigt-Straße 3  
 35039 Marburg  
 Germany  
 arweiler@med.uni-marburg.de



Our dental implants have  
an outstanding survival rate

98%

With maintained marginal  
bone after 5 years

0.3 mm



Stronger  
than ever.  
Thanks to  
science.

After 30 years of research and more than 1,000 scientific publications, we can confidently say that Astra Tech Implant System® EV delivers life-long function and natural esthetics.

Thanks to science, our implants have an outstanding survival rate and a marginal bone maintenance far better than the industry standard.

If you are looking for endless possibilities and superior outcomes, this is the only system you need. Today and tomorrow.

Follow Dentsply Sirona Implants  
for the latest in implant dentistry



[dentsplysirona.com/implants](https://dentsplysirona.com/implants)





# SEM investigation of implant surface characteristics

Drs Branislav Fatori & Inge Schmitz, Germany

**Implants have become** an essential part of restorative dentistry. Their success and long-term prognosis mainly depend on design, accurate manufacturing of their surface structure, bone quality, clinical skill and individual risk factors. Titanium implants have been used in dentistry with great success for more than 50 years and various surface modifications have been made to improve osseointegration. An ideal implant requires high levels of surface cleanliness in order to minimise the risk of foreign body reactions. Different implant systems have different surface properties, leading to different cell adhesion results.

## Objective

Contaminants from the manufacturing or packaging process can cause an uncontrolled foreign body reaction re-

sulting in the formation of high amounts of connective tissue, which leads to insufficient osseointegration. Against this background, the authors examined the surface characteristics of a new implant prior to its clinical use in their private practice. The implant was analysed using scanning electron microscope imaging (SEM) and energy-dispersive X-ray spectroscopy (EDX) in order to determine the elemental composition of potential impurities.

## Material


The investigated implant was a DSI RBM Premium Line implant (Dental Solutions Israel) made of titanium alloy Ti-6Al-4V ELI, in accordance with ASTM-F136-02. It has a spiral thread design with twin cutting grooves. The coronal micro-threads are designed to increase bone-implant contact and, in turn, long-term stability in the crestal area. The micro-rings on the implant neck are designed to minimise shear forces in the crestal zone and peri-implant bone loss. This tapered implant features a 2.42 mm internal hex connection, one abutment platform for all implant diameters (3.5–5.0 mm) and an increased fixture-abutment contact area. The apex is rounded and features self-tapping threads for optimal surgical flexibility.

## Implant surface

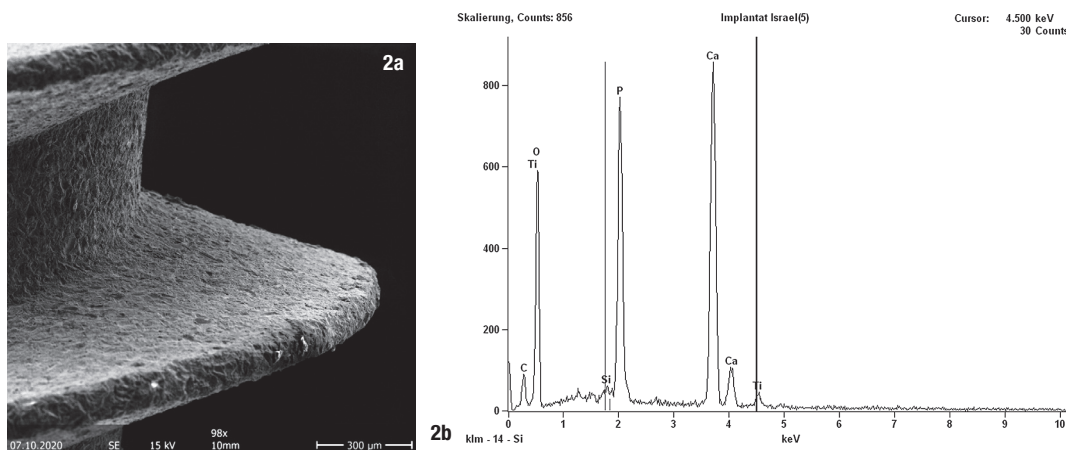
The investigated implant has a resorbable blast media (RBM) surface. During manufacturing, this surface is treated with high-speed particle blasting, using the resorbable bioceramic beta-tricalcium phosphate ( $\beta$ -TCP). The surface is cleaned and etched from calcium particles with a low concentrated organic acid. This process does not change the titanium surface pattern and produces a uniform surface with homogenous pore diameters and a greater bone-to-implant contact value (BIC).  $\beta$ -TCP, a resorbable material often used in synthetic bone grafts, dissolves during the healing process. The surface roughness value (Ra) is between 2.5 to 3.0  $\mu$ m. The micro-pits in the surface measure 1–3  $\mu$ m.

## SEM analysis

The Zeiss DSM 940 scanning electron microscope and the X-ray spectroscopy system NORAN System SIX



**Fig. 1:** Overview (a), detailed view of spirals and inhomogeneous rough surface (b), roughness of the surface with organic deposition is clearly visible (c), rough surface (d).



**Fig. 2:** View of coil with detached particle (a), EDX analysis shows peaks for calcium and phosphorus, which originate from surface treatment; spot analysis (b).

(Thermo Fisher Scientific) were used for analysis. Once unpacked and mounted on an SEM target, the sterile implant was immediately investigated without further coatings. It was observed that the spirals had regular intervals. The edges showed some inhomogeneities. A homogeneous porous surface was clearly visible. Small contaminations were found (Fig. 1). The energy-dispersive X-ray spectroscopy detected peaks for calcium and phosphorus, which originate from surface treatment (Fig. 2). Apart from that, small organic carbon particles as well as a few small particles composed of aluminium were detected. Low amounts of silicon were focally detected.


## Discussion

Today, implants can survive for a long time.<sup>1</sup> In a past study, the authors analysed eight sterile-packaged implants from different manufacturers.<sup>2</sup> They found that even implants in the low-budget segment can have good surface characteristics. The accurate topographic characterisation of dental implants is vital, as their surface microstructure affects osseointegration. The influence of Ra on growth of different cells has been extensively studied and it is known today that epithelial cells do not attach as strongly to acid-etched or sand-blasted surfaces as to smooth (polished, Ra <0.5 µm) surfaces, while fibroblasts adhere equally well to rough (such as machined) and smooth surfaces.<sup>3–5</sup> Other authors also suggest that metabolic activity (i.e. the production of osteocalcin, prostaglandin E2 [PGE2] and transforming growth factor-β1 [TGF-β1], or alkaline phosphatase activity) of osteoblast-like cells is significantly increased on rough (i.e. sand-blasted, etched or plasma-sprayed) surfaces. Inorganic materials, such as bio-reactive calcium phosphate or hydroxylapatite (HAp) coatings, have been applied extensively owing to their chemical similarity to bone minerals.<sup>6,7</sup>

## Conclusion

Osseointegration of foreign materials always causes a persisting foreign body reaction with the activation of macrophages and resulting inflammatory processes.<sup>8</sup> These general pathological reactions need to be kept low in order to reduce peri-implantitis, potential pathological alterations, or implant loss. Unfortunately, many implants show contaminations in the form of metallic or


inorganic particles, which originate from the manufacturing or packaging process.<sup>9–12</sup> These particles can cause implant failure. Reliable control mechanisms need to be put in place by manufacturers to ensure that only implants with minimum health risks for patients are sold. Additionally, irregularities in the shape or the structure of threads can support the deposition of unwanted particles.



## about the authors



**Dr Branislav Fatori** has more than four decades of experience in implantology. In addition to his German doctoral degree, he holds a second doctoral degree from the University of Belgrade in Serbia. He was trained at internationally renowned clinics and has worked as a consultant for implant manufacturers.



**Dr Inge Schmitz** has worked at the Institute of Pathology of the Ruhr-University Bochum in Germany since 1990. Her main interests are implantology, stents, electron microscopy and osteology. She studied biology at the same University and completed her PhD at the University of Essen in Germany in 1989.

## contact

**Dr Branislav Fatori**  
Rolandstraße 11  
45128 Essen, Germany  
Phone: +49 201 82188890  
info@fatori.de



**Dr Inge Schmitz**  
Georgius Agricola Stiftung Ruhr  
Institut für Pathologie  
Ruhr-Universität Bochum  
Bürkle-de-la-Camp-Platz 1  
44789 Bochum, Germany  
inge.schmitz@rub.de



# Mandibular dentigerous cyst

## Enucleation and bone reconstruction

Drs Fernando Duarte & Carina Ramos, Portugal

**The dentigerous or follicular cyst** is the most common type of developmental odontogenic cyst and the second most common among all that occur in the jaws, representing about 20 % of all cysts.<sup>1,2</sup> By definition, a dentigerous cyst is attached to the tooth cervix (cemento-enamel junction) and encloses the crown of the unerupted tooth. It is a benign lesion associated with the odontogenic epithelium of the crown of an unerupted tooth and originates from the separation of the follicle around the crown of the tooth in question, forming a cavity bounded by the reduced enamel epithelium and the tooth enamel, which is filled with cystic fluid.<sup>3</sup> As with other cysts, expansion of a dentigerous cyst is related to epithelial proliferation, release of bone-resorbing factors and an increase in cyst fluid osmolality.

### Aetiology and pathogenesis

Although its aetiopathogenesis is not fully known, it is believed that epithelial proliferation around a fluid-filled cavity grows continuously by osmotic pressure over an extended period, as long as the tooth does not erupt.<sup>3</sup> If this pressure is removed by the tooth erupting, the cyst will no longer be a pathological entity.<sup>3</sup>

### Histopathology

Histologically, the characteristics of dentigerous cyst are variable. If it is not inflamed, it has a loose and thin connective tissue capsule, covered by non-keratinised epithelial cells, composed of two or three layers of flat or cuboidal cells. When there is a secondary infection present, the connective tissue is denser and there is variable infiltration of chronic inflammatory cells. The lining epithelium may show variable levels of hyperplasia, developing epithelial ridges with more striking scaly characteristics.<sup>1</sup>

### Differential diagnosis

Differential diagnosis of pericoronal radiolucency should include odontogenic keratocyst, ameloblastoma and other odontogenic tumours. Ameloblastic transformation of a dentigerous cyst lining should also be part of the differential diagnosis. Adenomatoid odontogenic tumour would be a further consideration with anterior pericoronal radiolucencies, and ameloblastic fibroma would be a possibility for lesions occurring in the posterior of the jaws of young patients.<sup>3</sup>

### Clinical features

Dentigerous cyst occurs predominantly in the first three decades of life, has a predilection for the male sex and affects more Caucasian individuals. Although this pathology may occur in any unerupted tooth, the teeth most frequently affected are the mandibular third molars, maxillary canines and mandibular premolars.<sup>1,4</sup> The occurrence in primary dentition is extremely rare.<sup>5</sup> Clinically, these lesions are, in most cases, of slow and asymptomatic growth; however, they can grow considerably and cause expansion of the cortical bone, facial deformation, impaction or displacement of teeth and adjacent structures, paraesthesia and discomfort.<sup>6</sup> They may be associated with some syndromes, when they present in multiple or bilateral forms, such as Maroteaux-Lamy syndrome and cleidocranial dysplasia.<sup>6</sup> Radiographically, in most cases, dentigerous cyst appears as a radiolucent unilocular cavity with a well-defined sclerotic margin, involving the crown of an unerupted tooth, starting from the cemento-enamel junction, although multilocular aspects can also occur in large lesions.<sup>7,8</sup> While a normal dental

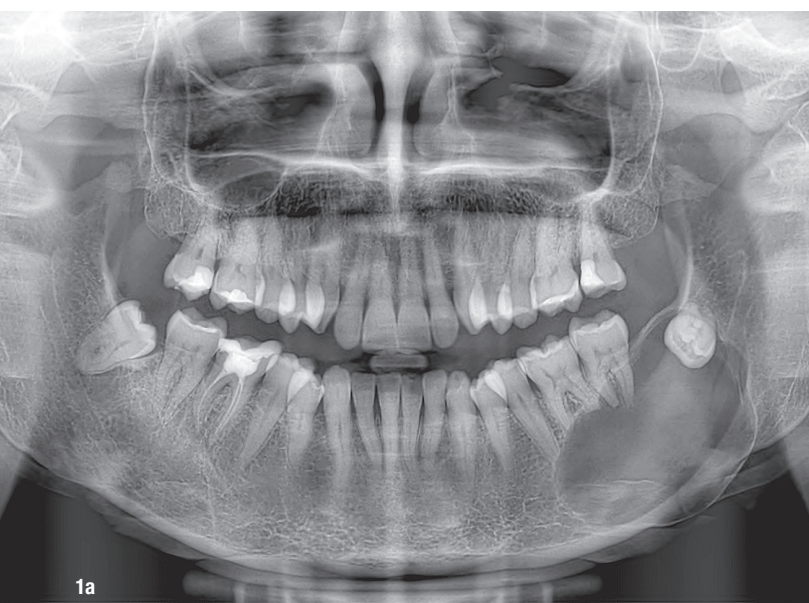

Fig. 1a: Initial dental panoramic tomogram.



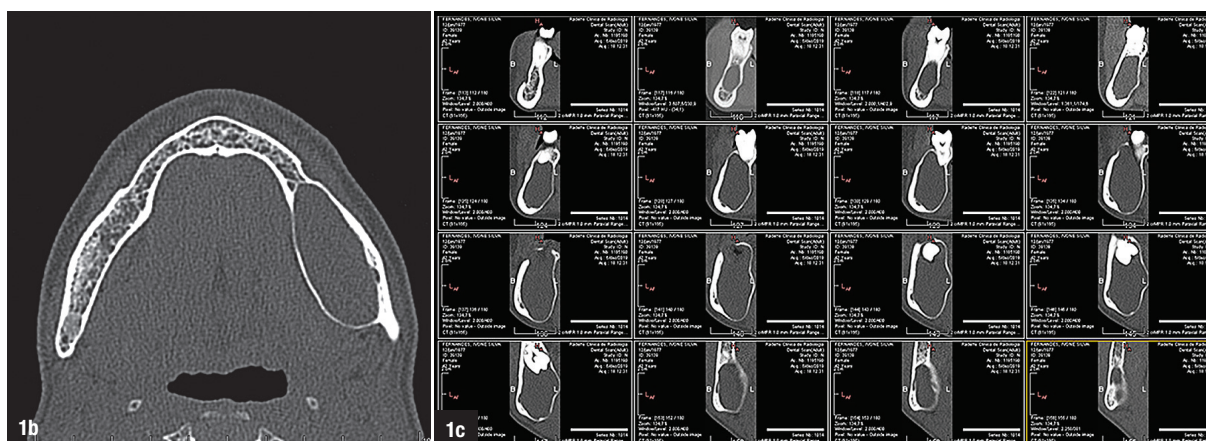


Fig. 1b: Initial CT sagittal section. Fig. 1c: Initial CT cross section.

follicle has 3–4 mm of space between the tooth and its margin, this cyst can be suspected when this space is larger than 5 mm.<sup>1,8</sup> When located in the mandible, this cyst can cause the displacement of the mandibular canal, the resorption of the wall of this canal, the root resorption of adjacent teeth or even pathological mandibular fracture.<sup>9,10</sup>

## Treatment options

Marsupialisation and enucleation are the classic techniques for the treatment of dentigerous cyst and may be associated.<sup>7,8</sup> Decompression, using a decompression device, is an option, when followed by enucleation, for the treatment of large cysts. However, the criteria for choosing one of these modalities are not clearly defined, owing to the lack of exhaustive studies and adequate follow-ups.<sup>11</sup> As accepted criteria for diagnosis and treatment, the size of the cyst, the age of the patient, the teeth involved and the involvement of anatomical structures must be taken into account.<sup>1</sup> The treatment modality to be chosen will depend on the clinical and radiographic characteristics in question. Lesion aspiration should be performed in all cases, as radiographically similar lesions can be odontogenic tumours or vascular lesions and not cysts as expected, the detection of fluid inside the lesion being a major indication of cyst.<sup>12–14</sup>

Incisional biopsy must then necessarily be performed to differentiate the type of cyst, as other lesions, such as odontogenic keratocysts and unicystic ameloblastoma, may have similar clinical and radiographic characteristics; however, they are more aggressive locally, requiring more extensive treatment and thus sacrifice of neurovascular tissue, bone and adjacent teeth.<sup>11,12,15</sup> The prognosis of dentigerous cyst is favourable and has a low recurrence rate (3.7%); even so, the follow-up must be strict.<sup>10</sup> Enucleation of the cyst and extraction of the associated unerupted tooth are performed in about 85% of cases and are the treatment of choice for small lesions with a

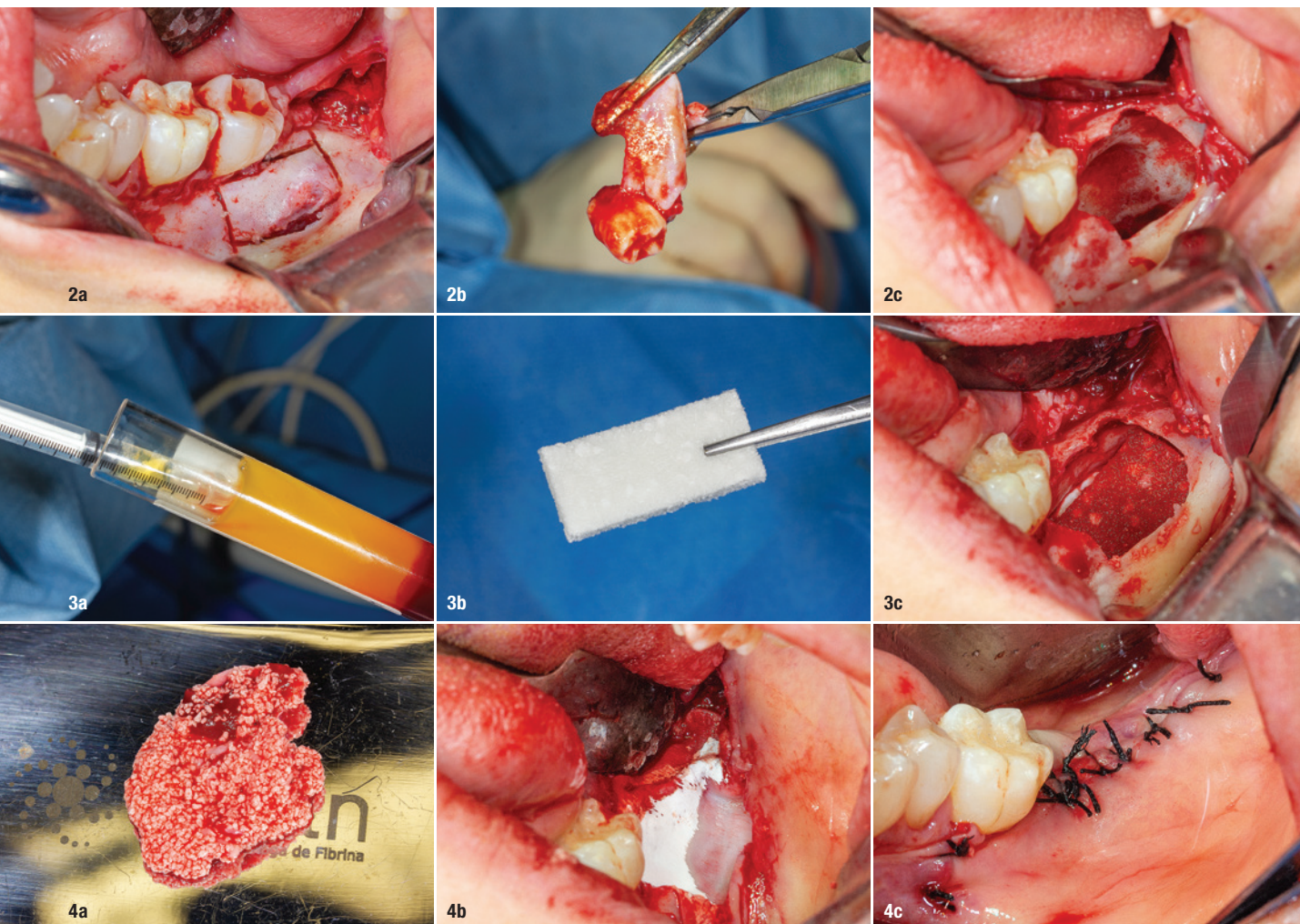
safe distance from anatomical structures, such as the inferior alveolar nerve.<sup>1,12</sup> In these patients, this is indicated if the unerupted tooth is considered useless for masticatory or aesthetic function or there is a lack of clinical space for its eruption.<sup>10,11,14</sup> In dentigerous cysts of third mandibular molars, the larger the cyst, the greater the risk of nerve injury and weakening of the mandibular angle caused by the surgery. Therefore, in these cases, the most appropriate therapeutic modality would be decompression followed by enucleation, after reducing the size of the lesion.<sup>16–18</sup>

## Bone reconstruction

The two-stage treatment is time-consuming, uncomfortable for patients and requires frequent check-ups. One-stage cystectomy of large cysts with watertight closure of the postoperative bone cavity predisposes to complications. Moreover, the weakened bone structure is prone to fractures in the postoperative period. This is why there is particular interest in filling the bone cavities with autografts or bone substitutes.

## Clinical case

A 43-year-old Caucasian female patient attended the oral and maxillofacial surgery consultation at Clitrofa medical centre in Trofa in Portugal to assess extraction of teeth #38 and 48. She was asymptomatic, without paraesthesia, hypoaesthesia or other complaints. Anamnesis established that there were no allergies or use of medication. On extra-oral clinical examination, no abnormality was observed. On intra-oral physical examination, a slight bulging of the cortical bone was noted in the region of the left external oblique line adjacent to tooth #37, but no chromatic alteration in the oral mucosa. The dental panoramic tomogram showed a unilocular, well-defined, homogeneous radiotransparent area surrounding the dental crown of the included tooth #38, extending to the tooth #35 region (Fig. 1a). In the coronal, sagittal and



**Fig. 2:** Osteotomy with piezoelectric surgery (a), cystic capsule with impacted tooth 38 (b), intraoperative image of the cystic cavity (c). **Fig. 3:** Platelet-rich fibrin (a), CERASORB® Foam used to protect the inferior alveolar nerve (b), intraoperative image of inferior layer of bone reconstruction (c). **Fig. 4:** Sticky bone for cystic cavity reconstruction (a), Osgide® resorbable membrane covering complete area of bone reconstruction (b), intraoperative image after suturing (c).

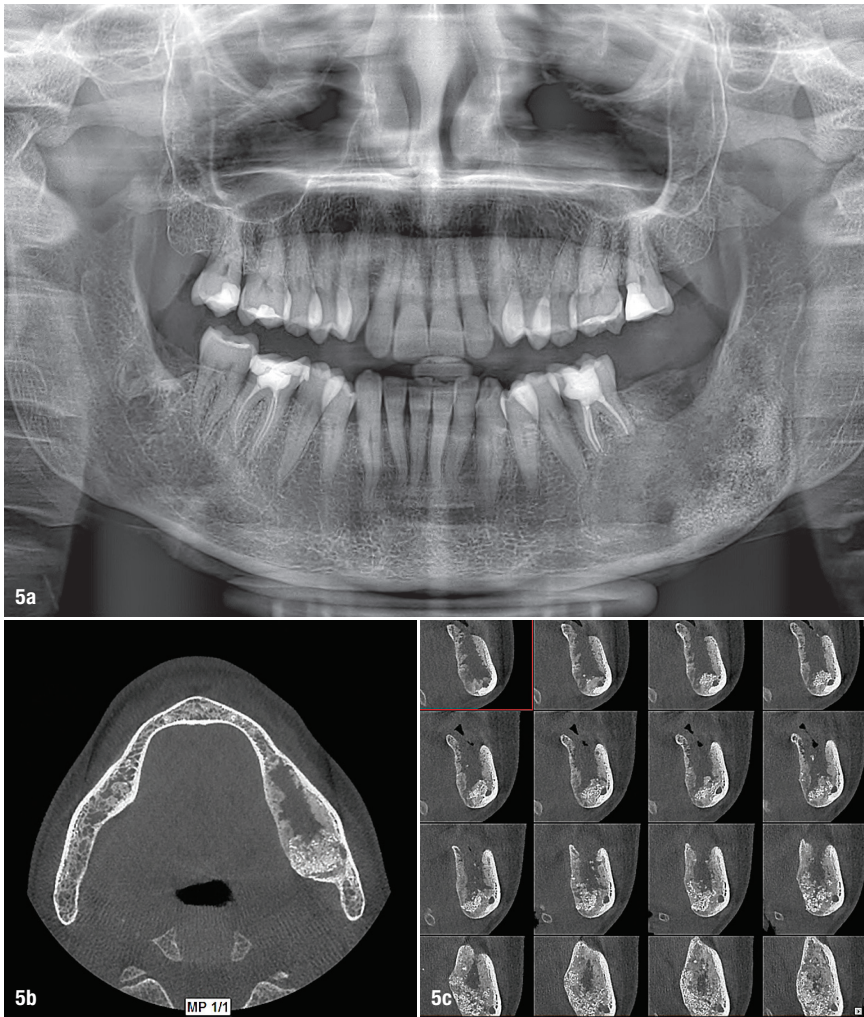
axial sections of the CT scan, it could be seen that the lesion was in close contact with the mandibular canal and there was cortical bulging (Figs. 1b & c).

As initial options for diagnosis, the possibilities of odontogenic keratocysts, unicystic ameloblastoma, adenomatoid odontogenic tumour and dentigerous cyst were considered. Aspiration puncture was performed under local anaesthesia, producing a small amount of light-yellow liquid and thus confirming the cystic nature of the lesion and working as decompression to reduce the lesion size. Endodontic treatment of tooth #36 was performed prior to surgical intervention. The patient was operated on under general anaesthesia, with nasal intubation. An intra-oral incision was made in the left retro-molar region that extended to the canine region, where a discharge incision was made. The osteotomy for access to the cystic cavity was performed by piezoelectric surgery. Based on 3D control of ultrasonic microvibrations, a micrometric and selective cut is allowed, under good

visibility (cavitation effect) that results in minimal damage to soft tissue and nervous structures (Fig. 2a).<sup>19</sup> The equipment used was the VarioSurg3 (NSK). The cystic capsule was excised together with the extraction of included tooth #38 and tooth #37 (Fig. 2b). The remaining cavity was cleaned with saline solution, keeping the lower border of the mandible intact (Fig. 2c).

Bone regeneration was performed with CERASORB® M (curasan) in granule and foam form combined with fibrin and Osgide® resorbable membrane (curasan). CERASORB® M is a resorbable and pure-phase beta-tricalcium phosphate ceramic for implantation filling, binding and reconstruction of bone defects, as well as bone fusion in the entire skeletal system. The granules have a polygonal shape, and owing to the open intercommunicating multi-porosity composed of micro-, meso- and macropores (about 65%), the radiopacity is lower and absorption is effected faster. Over months in contact with the vital bone, the material is resorbed by





**Fig. 5:** Final dental panoramic tomogram (a), final CT sagittal section (b), final CT cross section (c).

the body and simultaneously replaced by autologous bone tissue. As a synthetic and bioactive ceramic material, CERASORB® M has no local or systemic toxicity and no risk of allergic reaction. CERASORB® M is radiopaque and can be used in granule, paste and foam form.<sup>20</sup> The use of autologous platelet-rich fibrin (PRF) in the grafting process offers beneficial characteristics in the modulation of the inflammatory response, immune response and tissue repair, tissue reorganisation and angiogenesis (Fig. 3a).<sup>21</sup> The association of PRF with mineral biomaterials (I-PRF) facilitates handling and application and allows immediate adhesion to the receiving bed (Figs. 3b & c).<sup>21</sup>

The inferior layer of bone reconstruction was performed with CERASORB® Foam soaked with PRF in an attempt to protect

the inferior alveolar nerve integrity and strengthen the lower border of the mandible. The superior reconstruction layer was done with CERASORB® M granules combined with PRF, creating what is described as sticky bone. Sticky bone provides stabilisation of the bone graft in the defect and is easy to manipulate and therefore accelerates tissue healing and minimises bone loss during the healing period (Fig. 4a). An Osgide® resorbable membrane was used to cover the bone reconstruction. Osgide is a bio-resorbable barrier membrane for use in guided tissue regeneration and guided bone regeneration. The membrane creates a protective environment for bone regeneration in the defect area and supports osteoneogenesis by presenting a barrier to the infiltration (migration) of soft tissue and promoting the growth of osteogenic cells in the bony defect



## Shortest Implants – Longest History.

## Think Short!

For more than 30 years Bicon® short implants are unchanged in clinical use.

According to the 11<sup>th</sup> European Consensus Conference (EuCC) 2016 in Cologne, provided the specific treatment parameters are observed, the use of short, angulated or diameter-reduced implants in sites with reduced bone volume can be a reliable treatment option, given the risks associated with the use of standard-dimension implants in combination with augmentation procedures.

For more Information:

**Bicon Europe Ltd.**

Dietrichshoehe 2

55491 Buechenbeuren

Germany

Phone +49 (0)6543 818200

germany@bicon.com

**www.bicon.de.com**



**bicon®**  
DENTAL IMPLANTS



(Fig. 4b). Suturing was performed with simple stitches using non-resorbable thread (silk, 4/0; Fig. 4c).

The patient underwent systemic antibiotic, analgesic and anti-inflammatory therapy for eight days. In postoperative care, the patient was instructed to maintain strict oral hygiene. The material obtained from the cystic cavity was sent for pathological examination, and the findings were islands of odontogenic epithelium remains scattered in the fibrous connective tissue capsule, composed of three layers of flattened, non-keratinised cells. These findings confirmed the diagnosis of dentigerous cyst. At the time of writing, the patient was in the postoperative period of 12 months and had shown no hypoaesthesia or any sign of recurrence of the lesion. In the postoperative dental panoramic tomogram (Fig. 5a) and CT scan, there was evidence of bone neo-formation in the area previously occupied by the lesion (Figs. 5b & c).

## Discussion

Among the possible treatment techniques for dentigerous cyst, the most suitable for each clinical situation should be evaluated, considering all scenarios for each option.<sup>7</sup> In the present clinical case, had the treatment been decided on considering only the size of the lesion, enucleation would have been the most appropriate choice associated with the extraction of the impacted tooth #38. Owing to the proximity of the inferior alveolar nerve, decompression followed by cyst enucleation and extraction of the tooth in question was the most reasonable option. This allowed bone regeneration of the cystic cavity, as well as maintenance of nerve integrity. Enucleation is the technique of choice for cysts of smaller dimensions and when there is no involvement of important anatomical structures, since it provides the possibility of a histological study of the lesion.<sup>1,12</sup> Marsupialisation and decompression with the use of a device should be reserved for clinical cases of extensive dimensions, involving important anatomical structures and increased risk of fracture, as they promote the reduction of intracystic pressure, consequently reducing the size of the lesion.<sup>7,8,10,11,18</sup> Taking into account this objective of decompression, it was decided in this clinical case to maintain the lesion–oral cavity communication created during the aspiration puncture, which, although reduced, was sufficient to regress the dimensions of the lesion.

Both marsupialisation and decompression are therapeutic modalities also indicated in the period when the bone repair capacity is high and the eruptive power of the teeth is present.<sup>10,11</sup> Sticky bone is biologically solidified bone grafting material which is entrapped in fibrin network. Sticky bone graft granules are strongly interconnected to each other by the fibrin network. Sticky bone has numerous advantages:

1. It is mouldable, so it adapts well to various shapes of bony defects.
2. Micro- and macro-movement of grafted bone is prevented, so the volume of augmentation is maintained during the healing period. Therefore, the need for block bone and titanium mesh is minimised.
3. Fibrin network entraps platelets and leucocytes to release growth factors, so bone regeneration and soft-tissue growth are accelerated.
4. No biochemical additives are needed to make sticky bone.
5. Fibrin interconnection minimises soft-tissue ingrowth into the sticky bone graft.<sup>21</sup>

## Conclusion

Dentigerous cyst is a frequent lesion which, despite being a less aggressive pathology and without clinical symptoms, has the potential to reach large proportions, causing significant movement of teeth. The treatment decision must be based on objective criteria, such as age of the patient, size of the lesion, involvement of relevant anatomical structures, clinical importance of the tooth or teeth associated with the lesion, and risk of bone fracture. It is essential to perform a histopathological examination for the differential diagnosis, ruling out other types of lesions with similar clinical and radiographic characteristics, as well as to perform annual postoperative radiographic monitoring.



## about the author



**Dr Fernando Duarte** is a Portugal-based dentist who specialises in oral surgery. He holds a postgraduate qualification in oral and maxillofacial surgery and a master's degree in oral and maxillofacial surgery from Eastman Dental Institute at University College London in the UK. Dr Duarte is the CEO and clinical director of the Clitrofa medical centre in Trofa in Portugal.

## contact

### Dr Fernando Duarte

Clitrofa—Centro Médico, Dentário e Cirúrgico  
Avenida de Paradela 626  
4785-342 Trofa  
Portugal  
Phone: +351 252 428960  
fduarte@clitrofa.com



# AUTUMN OFFER 2020

Show what you're made of—with precision from PreXion.

## EXPLORER<sup>PreXion3D</sup>

### Variety of volumes

From 5x5cm to 15x16cm (without stitching)

### Outstanding image quality

Resolution of up to 74µm

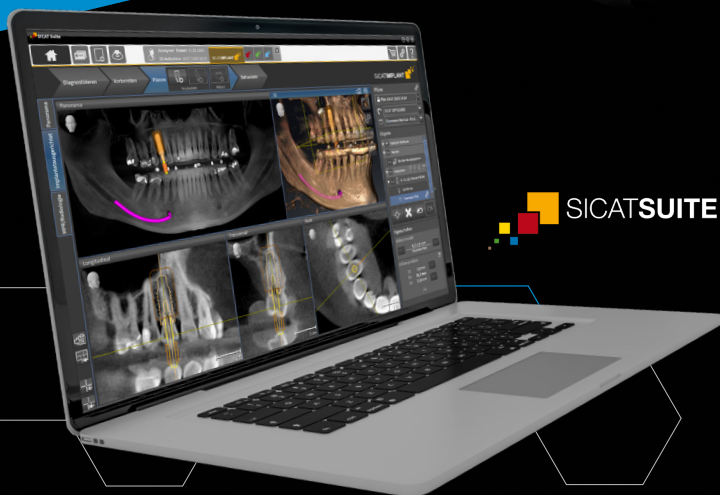
Focal spot of only 0,3x0,3mm

### Integrated 2D One-Shot CEPH program

Without cephalometric arm

Special price  
PreXion3D EXPLORER DVT

Special package deal  
SICAT Suite



PreXion (Europe) GmbH

Stahlstraße 42-44 · 65428 Rüsselsheim · Germany

Tel.: +49 6142 4078558 · info@prexion-eu.de · www.prexion.eu

# Combining **standard** and **ultrashort** implants in full-mouth rehabilitation

## 18 months of follow-up

Drs Giovanni Ghirlanda, Michele Vasina & Laura C. Campos, Italy

### Introduction

The use of shorter implants was introduced in the early 1990s to overcome the necessity of complex and expensive bone augmentation procedures associated with implant therapies. In recent years, different proposals have been made regarding the length that would classify implants as short in comparison with standard implants. Now, there is consensus that implants with a length of  $\geq 8$  mm are considered as standard, 6–8 mm long implants are classified as short and implants with a length of  $< 6$  mm are defined as ultrashort.<sup>1</sup>

Since 2011, the results of several clinical trials regarding the predictability and the clinical reliability of ultrashort implants have been published, considered by themselves or in comparison with some of the most commonly utilised guided bone regeneration procedures. In 2012, Felice and co-workers reported a significant minor occurrence of complications in relation to 5x5 mm hydroxyapatite-coated implants compared with 11.5 mm long implants placed in augmented bone after six months of follow-up in a randomised clinical trial conducted on 80 patients (40 of them with a reduced height of bone below the maxillary sinus and 40 over the mandibular nerve).<sup>2</sup> In a single cohort study on 110 implants, followed up for five years, Perelli and colleagues described a cumulative success rate of 90% for the implants and 93% for the prosthetic rehabilitation.<sup>3</sup> In 2015, Esposito et al. published the results of three years of follow-up results of the same group of patients, who presented with significantly less marginal bone loss for the implants placed in the maxilla and no differences for the ones in the mandible.<sup>4</sup>

More recently, in 2016, the same researchers started a multicentre clinical trial on 4x4 mm implants. They published the preliminary report of a one-year follow-up, in which they did not find differences in the outcomes between ultrashort and standard (at least 8.5 mm long) implants.<sup>5</sup> It should be pointed out that the patients participating in the study received a three-unit implant-supported prosthesis, for which there was at least one standard implant, in the absence of significant

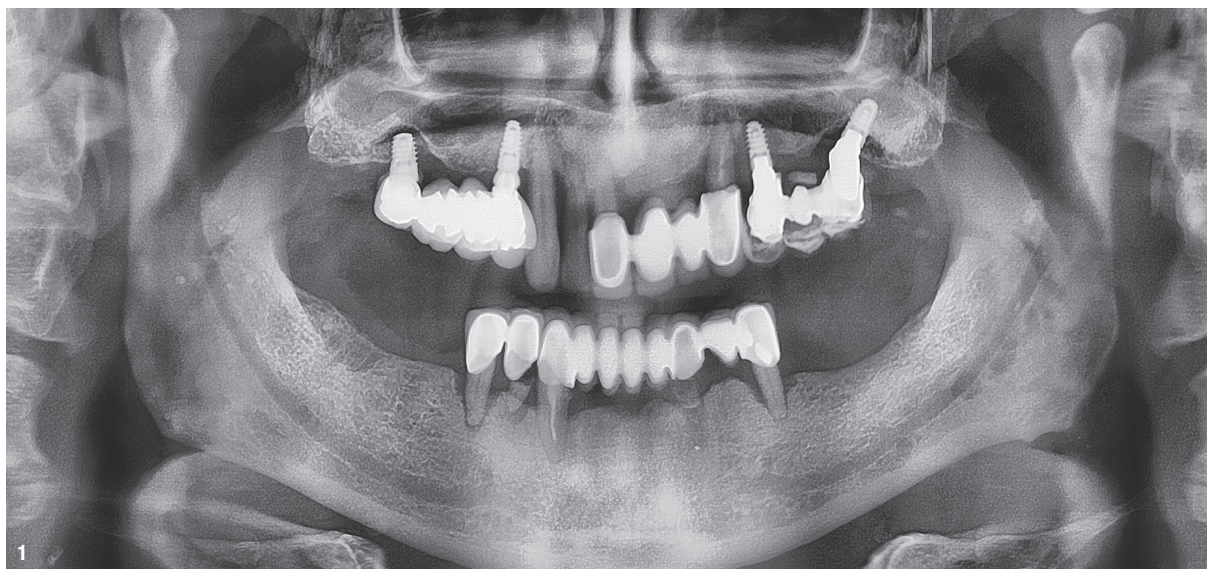bone atrophy. Diversely, a recent review by Papaspyridakos et al. compared the clinical efficacy of ultrashort implants and longer implants.<sup>6</sup> The multivariate analysis described in this review assigned an odds risk ratio of 1.29 to the  $\leq 6$  mm implants compared with the standard ones. A common conclusion of papers on short implants is that they are advantageous in that they present significantly fewer postoperative complications and are faster and simpler for patients with significant bone resorption and that treatments are less expensive for such patients.

Immediate loading is a therapeutic approach that has demonstrated long-term results regarding high reliability and efficacy.<sup>7</sup> It is beyond the aim of this case report to describe the evidence that supports the predictability of this approach. However, it has been definitively stated that primary stability is a key factor for success. Achieving a sufficient degree of primary stability with short and, above all, ultrashort implants is a true challenge. Anitua published a case series of ten immediately loaded implants in the posterior maxilla with more than four years of follow-up.<sup>8</sup> Among the implants placed, five were 7.5 mm in length and the other five 8.5 mm. Nine out of ten implants (cumulative success rate of 90%) were considered stable at the follow-up. In 2018, Weerapong et al. compared 23 immediately loaded short implants of 6 mm in length with 23 conventionally loaded standard implants of 10 mm in length.<sup>9</sup> All the cases evaluated were intercalated mandibular first molars. They concluded that the results achieved with immediate loading of the short implants was comparable to those achieved for the standard implants in terms of implant survival, marginal bone level change and implant stability quotient value. To the best of our knowledge, there are no published papers reporting on immediate loading on ultrashort implants. The following case report describes an implant-supported full-mouth rehabilitation realised with a combination of ultrashort and standard implants with a follow-up of 18 months.

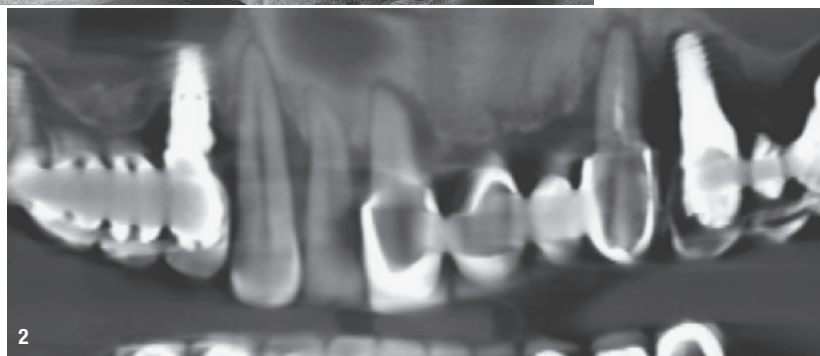
### Clinical case

The 66-year-old male patient, classified as ASA II, presented to the clinic complaining of pain, mobility and





**Fig. 1:** Dental panoramic tomogram of the patient, showing severe bone resorption. **Fig. 2:** CBCT scan showing the sinus floor and reduced bone height on both sides of the maxilla.



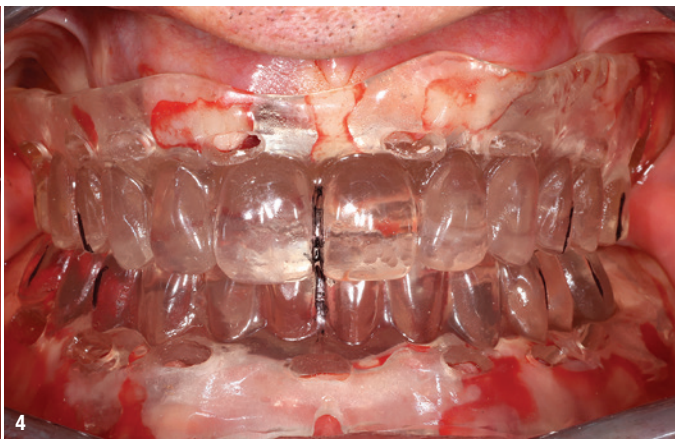
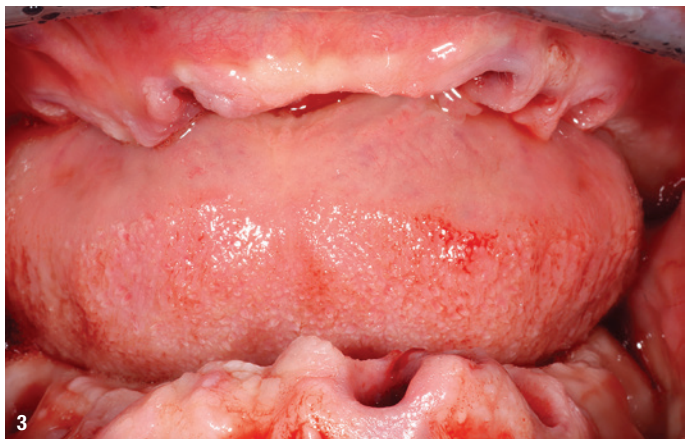discomfort in the maxillary left region. The clinical examination revealed advanced periodontal disease, Grade C and Stage IV according to the new periodontal disease classification. Spontaneous bleeding, suppuration and a general high degree of inflammation were evident.<sup>10</sup> He had metal–ceramic crowns in the lower jaw and three different bridges in the maxilla. All of them were extremely mobile, to between Grade II and Grade III. The panoramic radiograph showed a diffuse and advanced level of bone resorption extending to all remaining teeth (Fig. 1). Four implants were in the upper jaw, two of them with deep bone defects all around the implant bodies. The CBCT scan confirmed the teeth diagnosed on the panoramic radiograph and evidenced a large, deep bone defect extending from the canine beyond the left first premolar and a very low bone height below both the right and left sinus floor (Fig. 2). The left sinus appeared almost totally filled with inflammatory hyperplastic tissue.

Based on the clinical and radiographic examinations, all the teeth of the patient as well as the implants in positions #16 and 24 were evaluated as unsalvageable. On the contrary, the fixtures in positions #14 and 27 were stable and usable. The patient did not want to wear a removable prosthesis during treatment, not even for a short period. He also expressed his expectations about the level of aesthetics. For this reason, the treatment plan that was decided on was immediately loaded full-mouth implant rehabilitation in both jaws. Thereafter, a diagnostic wax-up was done, and it was decided not to modify the habitual occlusal vertical dimension of the patient at this stage of treatment. The dental technician created two surgical templates and two prosthetic templates for the impression, according to the protocol al-

ready published by Ghirlanda et al. Intravenous sedation and local anaesthesia (Scandonest 2%, 1 : 100,000 adrenaline; Septodont) were administered.<sup>11</sup> First, all of the remaining teeth and mobile implants were extracted (Fig. 3). Thereafter, the prosthetic templates were tried in to check the occlusion and the reproducibility of the diagnostic wax-up (Fig. 4). The maxillary template was then stabilised to the abutments screwed on to the existing implants.

Afterwards, a full-thickness periosteal flap was raised in the mandible, and the bone crest was flattened using a round bur mounted on a surgical handpiece under irrigation with sterile saline. Four implants (blueSKY, bredent medical), two axially placed (4x12mm) and two tilted (4x10mm, 4x12mm), were then placed, and the flap was sutured with interrupted sutures. All implants had an insertion torque of  $\geq 35$ Ncm. Four multi-unit abutments (SKY fast & fixed, bredent medical), two at 0° and two at 35°, were then screwed into the fixtures at 25Ncm. According to the cited immediate loading protocol,<sup>11</sup> the prosthetic copings were positioned on the multi-unit abutments, instead of the impression transfers, and then the prosthetic template was adapted to the implant positions. A light-polymerised composite (compoForm, bredent medical) was light-polymerised to join the pros-



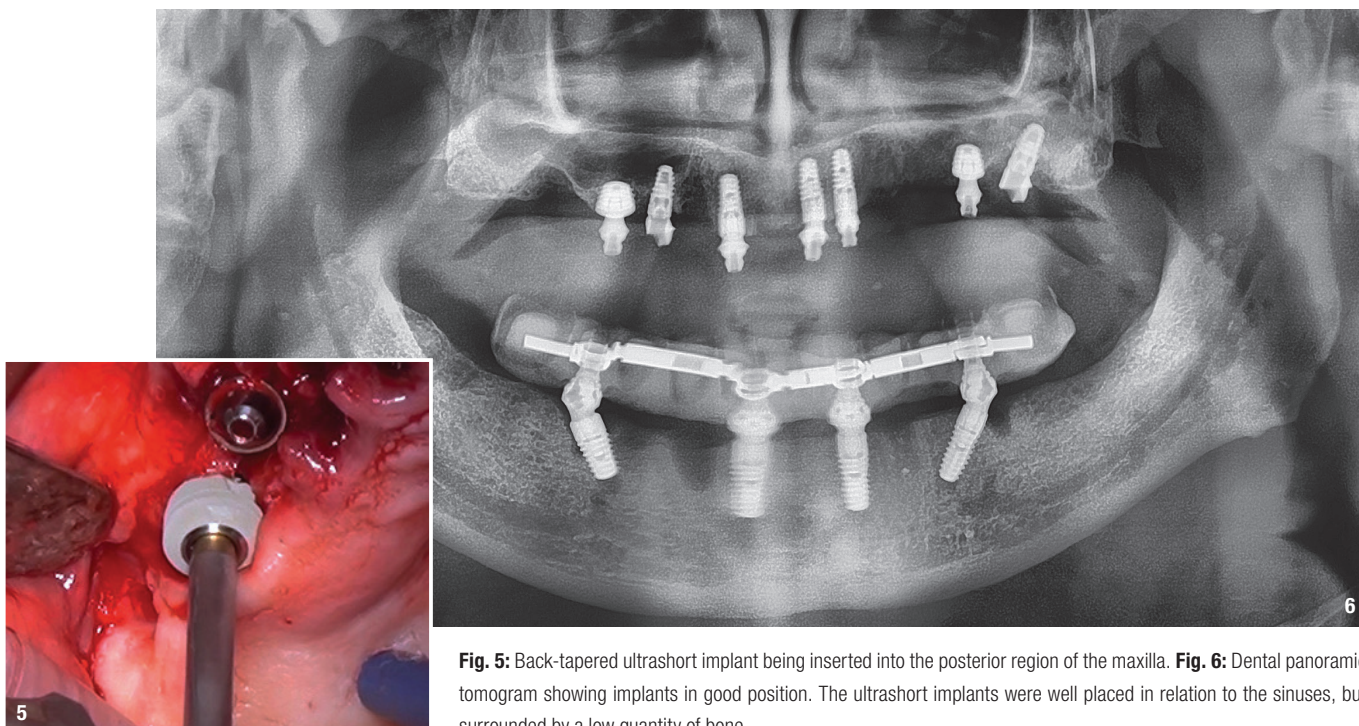


**Fig. 3:** Extraction of all compromised teeth and implants. **Fig. 4:** Prosthetic templates used to check occlusion and assure reproducibility.

thetic copings with the template positioned in centric occlusion of the patient. Once the polymerisation process was complete and the perfect stability of the template to the copings had been checked, a light impression material was injected below the template through the small holes that had been prepared in advance. Afterwards, the mandibular prosthetic template was sent to the laboratory for the production of the temporary prosthesis.

Thereafter, a full-thickness flap was elevated that extended all along the maxillary arch. Careful debridement was performed to remove all the inflammatory and fibrous tissue and to expose all the bone defects. Afterwards, the shallow defects were reshaped with bone chisels and round burs, while the deep defects were filled

with xenograft (Geistlich Bio-Oss, Geistlich Biomaterials) and covered with a resorbable barrier (Geistlich Bio-Gide, Geistlich Biomaterials). In the anterior region, standard implants were inserted (blueSKY), while in the first molar sites, two 5.2x6.0mm fixtures (copaSKY, bredent medical) were inserted (Fig. 5). To maximise the degree of primary stability of the ultrashort implants, bicorticalism was considered for the creation of an in-fracture of the sinus floor by means of osteotomes so that the ultrashort implants would have improved stability. The fixtures did not protrude into the sinus, nor was there evidence of elevation of the sinus mucosa. All the implants achieved a primary stability of  $\geq 35$  Ncm. The panoramic radiograph taken at the end of the surgery showed the correct positioning of the implants (Fig. 6).



**Fig. 5:** Back-tapered ultrashort implant being inserted into the posterior region of the maxilla. **Fig. 6:** Dental panoramic tomogram showing implants in good position. The ultrashort implants were well placed in relation to the sinuses, but surrounded by a low quantity of bone.



**Fig. 7:** Occlusion check for the immediate temporary prostheses delivered to the patient. **Fig. 8:** Clinical situation of the soft tissue in the maxillary and mandibular arches after two months with temporary prostheses in place. **Fig. 9:** Definitive prostheses at delivery. **Figs. 10a & b:** Satisfied patient with beautiful smile and improved facial profile.

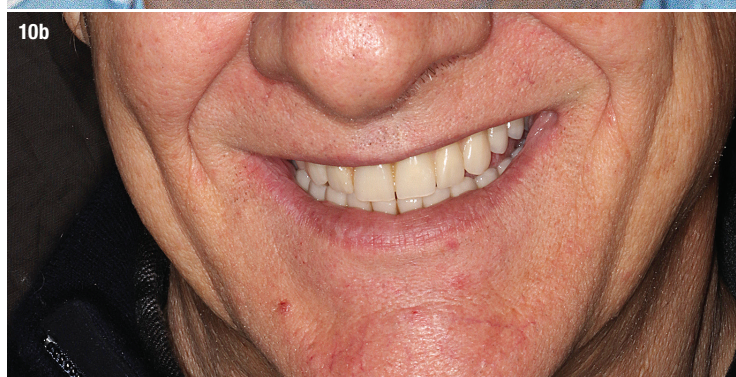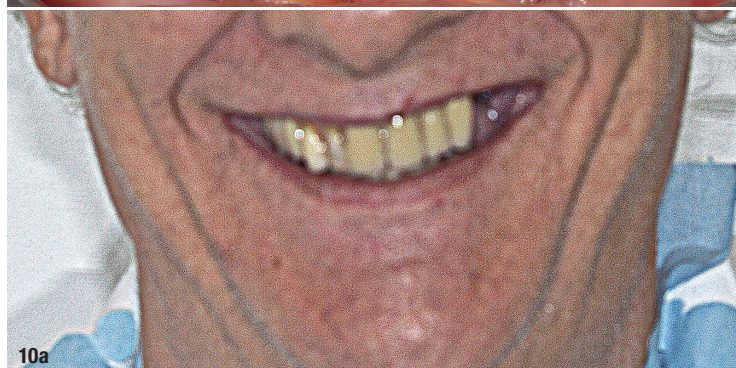
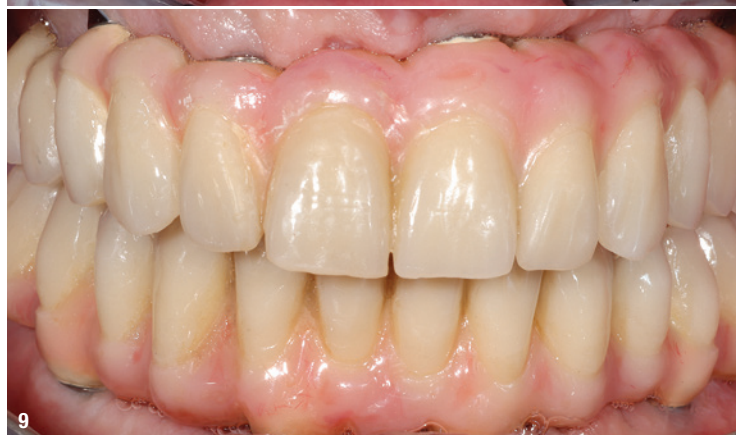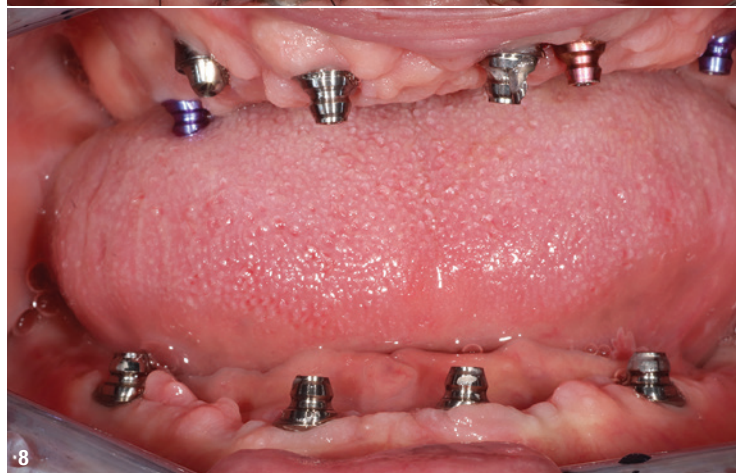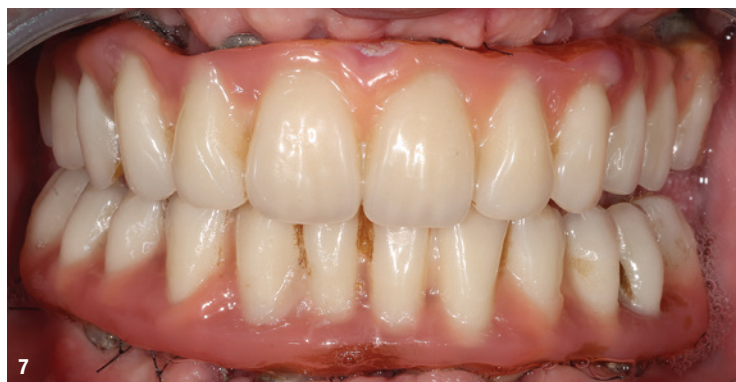Afterwards, the same impression protocol already described was followed for the maxillary temporary rehabilitation. To stabilise the maxillary prosthetic template in centric occlusion, the temporary mandibular prosthesis, delivered in the meantime from the laboratory, was positioned and checked. Once the impression phase had been completed, the prosthetic template was sent to the laboratory and the flap sutured with interrupted sutures. After two hours, the maxillary temporary prosthesis was delivered, and the occlusal contacts were checked and balanced (Fig. 7). The patient was discharged with a prescription of amoxicillin (875mg) in combination with clavulanic acid (125mg), twice daily for six days, and ibuprofen (600mg) and 0.12% chlorhexidine mouthrinses, starting from the following day for three weeks. The post-operative phase was uneventful, and the patient was reviewed every two weeks for two months, after which the prostheses were unscrewed, and each implant was evaluated. None of the implants showed signs of inflammation or mobility (Fig. 8).

Thereafter, the occlusal vertical dimension of the patient was readapted, adding occlusal stents joined to the temporary prostheses until a correct and fully comfortable balance was accomplished. For the definitive prostheses, two titanium bars were made, and composite dental veneers were positioned over the bar in the laboratory. The pink aesthetic portion of the prostheses was also achieved with composite (crea.lign, bredent medical). The definitive titanium and composite prostheses were then delivered to the patient (Figs. 9 & 10).

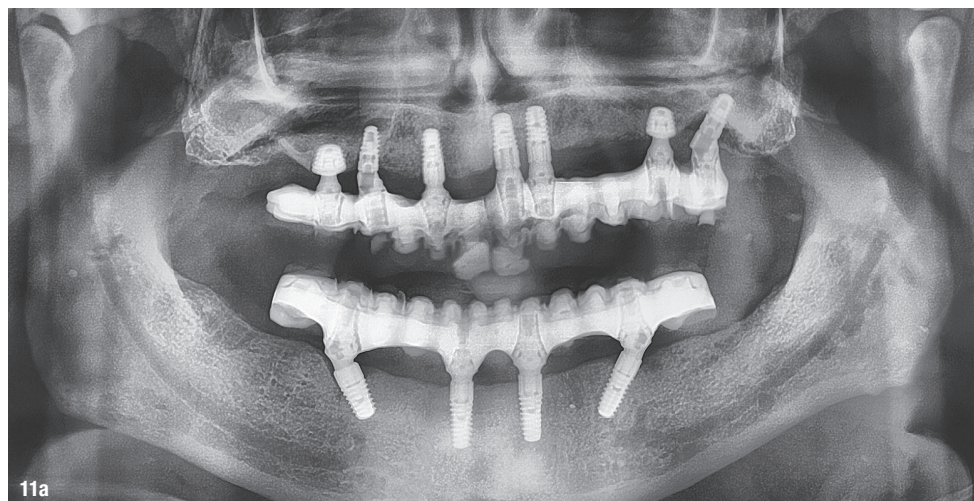
Afterwards, he was reviewed on a six-monthly basis. At the time of writing this report, the patient was followed up for 18 months. During this period, the only minor complication was the breakage of an incisal edge of a central incisor, which was repaired chairside. After 18 months, the panoramic radiograph control revealed perfect stability and even an improvement of the bone levels around all the implants placed. The ultrashort implants, especially, revealed a better bone density all around the bodies of the fixtures and at the top, where an increased amount of bone height was present in comparison with the immediate postoperative panoramic radiograph (Figs. 11a & b).

## Discussion

The case described in this article provides the first clinical evidence of immediate loading with standard implants in combination with the ultrashort implants that

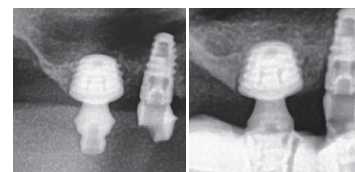






**Fig. 11a:** Dental panoramic tomogram at the 18-month follow-up, showing increased bone density around the ultrashort implants. **Fig. 11b:** Comparison of the bone quality to the right and left of the ultrashort implants at time of insertion and at 18 months.

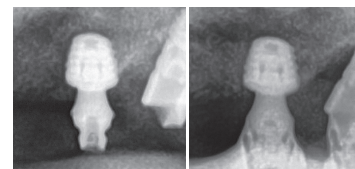
RHS



At insertion

At 18 months

LHS



At insertion

At 18 months

11b

were placed in the sites with poor bone quality. Ultrashort implants have already demonstrated substantial reliability in situations where the anatomy of the site does not allow the placement of a standard implant.<sup>5,12</sup> Even shorter implants than those used in the case described here have been successfully used. However, it has to be highlighted that the loading protocol utilised in the study design of those papers was a conventional one. Nowadays, immediate loading is considered a valid option among the possible approaches in implant treatment, especially using standard implants that are inserted into bone of good quality.<sup>7</sup> In the literature, there is only one clinical trial in which single short implants of 6 mm in length were compared with standard measures in the rehabilitation of a mandibular first molar.<sup>9</sup> There are some differences, beyond the negligible differences in length, between the design of the cited study and this case report. First, whereas our ultrashort implants were placed in an edentulous arch, in the study of Weerapong and colleagues, they were placed in the saddle area between the second molar and the first premolar.<sup>9</sup> Second, the implants were inserted into the mandible, whereas in our case they were placed in the maxilla in the regions of poor bone quality.

Anitua's case series reported a nine out of ten success rate for 8.5 and 7.5 mm long implants. The present case was followed for 18 months, during which only a minor prosthetic complication was noted.<sup>8</sup> The radiographic control showed perfect stability of the bone levels around all the implants. An improvement of the bone height and quality around the ultrashort implants was also evident. Theoretically, this evidence can be related to the anchorage to the sinus floor cortical bone that was intentionally searched in order to improve the degree of primary stability. Furthermore in Anitua's cases, no other procedure was performed, nor was grafting material used in the sites of the ultrashort implants.

## Conclusion

This case report has shown the successful outcome of an immediately loaded full-mouth implant-supported prosthetic rehabilitation. The medium-term follow-up, 18 months, and the radiographic evidence support a positive clinical outcome of the case presented. Further studies and clinical series are necessary to validate the choice of ultrashort implants in relation to the immediate loading approach as a useful means of overcoming anatomical challenges related to the placement of standard implants.

Literature



## about the author




**Dr Giovanni Ghirlanda** specialises in oral surgery, periodontics and implantology. He graduated in dentistry and dental prosthetics and later completed a master's programme in implantology at the University of Murcia in Spain. In 1992, he was a visiting lecturer at Harvard School of Dental Medicine in Boston in the US. From 1996 to 1999, he was an adjunct professor at the Sapienza University of Rome in Italy. He is a member of the Italian Society of Osseointegration.

## contact

### Dr Giovanni Ghirlanda

Via Mantova 1  
00198 Rome RM, Italy  
Phone: +39 06 8840120  
www.dentistromacso.it

Author details



# SUBSCRIBE NOW!

implants—international magazine of oral implantology

Interdisciplinary, transparent & market orientated

ONLINE  
SUBSCRIPTION HERE



www.oemus-shop.de



## stay updated:

research  
**Professional implant management**

case report  
**Combining standard and ultrashort implants in full-mouth rehabilitation**

**Interproximal root spreading for narrow implant placement**



Fax: **+49 341 48474-290**

I would like to subscribe for the following journals:

☐ implants—international magazine of oral implantology 4 issues p.a. € 44\*

☐ ceramic implants—international magazine of ceramic implant technology 2 issues p.a. € 30\*

Terms & Conditions: The subscription may be cancelled in written form without due justification within 14 days of order by contacting OEMUS MEDIA AG, Holbeinstraße 29, 04229 Leipzig, Germany. Dispatching notification in good time will suffice. The subscription is automatically extended by another 12 months if it is not cancelled in written form 6 weeks prior to the end of the reference period.

\* All prices include VAT, shipping and handling.

\_\_\_\_\_  
Last Name, First Name

\_\_\_\_\_  
Company

\_\_\_\_\_  
Street

\_\_\_\_\_  
ZIP, City, Country

\_\_\_\_\_  
E-mail

\_\_\_\_\_  
Signature

\_\_\_\_\_  
Credit Card Number

\_\_\_\_\_  
Expiration Date

\_\_\_\_\_  
Security Code

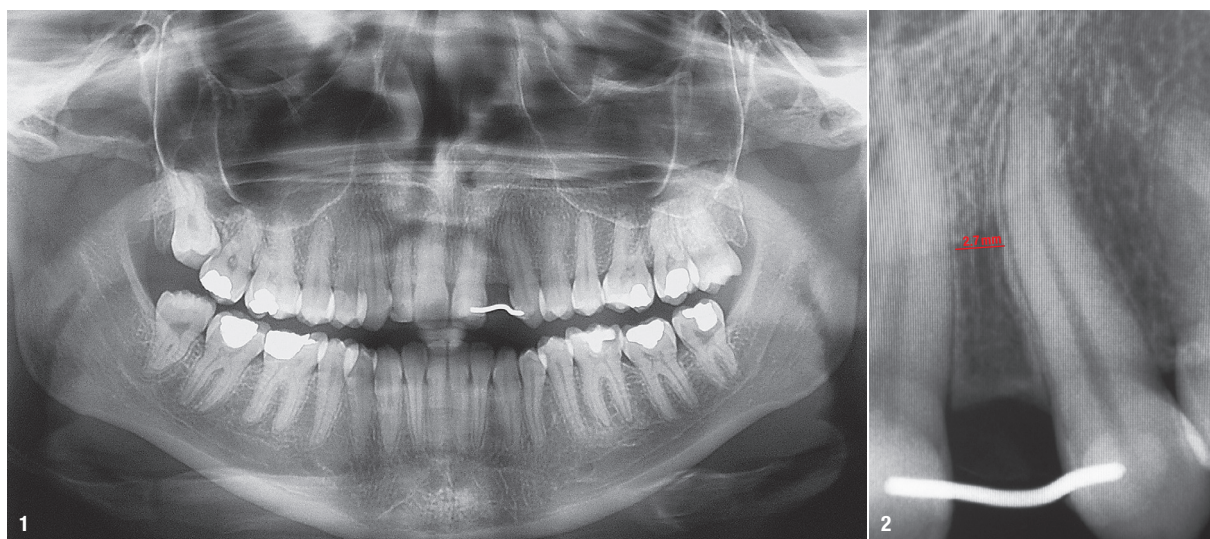# Interproximal **root spreading** for narrow implant placement

Dr Mauro Marincola, Dr Laura Murcko, Dr Giorgio Lombardo & Prof. Rolf Ewers, Italy, Austria & USA

## Introduction

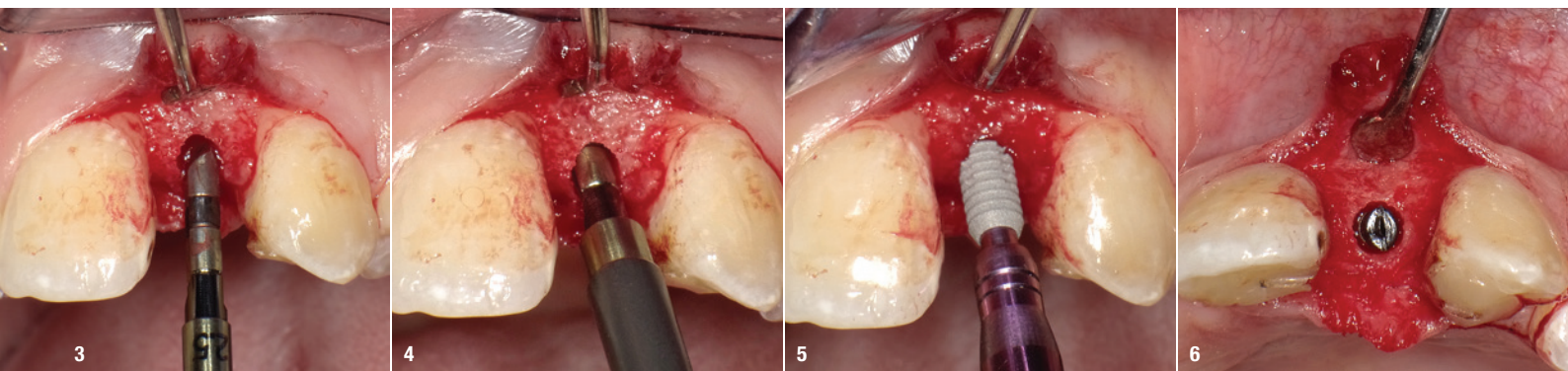
Congenitally missing lateral incisors are quite common. In some communities, we observe an incidence of up to 3% in the young population. Today, these teeth can be successfully replaced with dental implants.<sup>1</sup> Very often, these patients must undergo orthodontic treatment to obtain the adequate mesiodistal and buccopalatal dimensions. In many of these cases, the distances between the two neighbouring teeth remain critical because the orthodontist has moved the coronal part, but the roots still remain critically close to one another.<sup>2</sup> Narrow implants are becoming the ideal treatment option in case of reduced bone volume.<sup>3–6</sup> An accurate literature review on the correct protocol to follow during treatment planning for narrow spaces in the maxillary anterior region leads us to the conclusion that the minimum width for narrow implant placement (3.0–3.3mm diameter) to replace a maxillary anterior tooth should respect a 5mm distance between the neighbouring roots and a 5mm buccopalatal measurement for a minimum width which would assure a good prosthetic outcome and avoid the phenomenon of pressure necrosis. Areas involving dense bone seem to be at increased risk of compression necrosis.<sup>7,8</sup>

According to Salama et al., Tarnow et al. and Cardaropoli et al., it is important for the correct insertion of threaded implants, both in simple and complex cases, to maintain a minimum distance between implants (3mm) and between the implant and an adjacent tooth (1.5–2.0mm) in order to maintain an adequate interproximal bone crest and therefore the possibility of having a natural papilla as well as having a correct prosthetic design.<sup>9–11</sup> Sometimes, these cases present a Cawood and Howell Class IVa bone anatomy, and ridge expansion procedures can be performed to widen the crest. In cases with a Cawood and Howell Class IVb, where the crest has a bicortical fusion and no expansion procedures are possible, only bone grafting procedures such as guided bone regeneration or Khoury's box technique can resolve the situation.<sup>12,13</sup> The following case report demonstrates that, with the spreading technique, natural roots can be displaced, and demonstrates how important the implant design can be. Plateau-form press-fit implants do not compress the adjacent bone structures because of the presence in their design of healing chambers throughout most of the implant body. Only the edges of each plateau are in direct contact with the osteotomy walls, avoiding pressure necrosis. Also,



**Fig. 1:** Panoramic radiograph. Note the narrow space at position #22. **Fig. 2:** Periapical radiograph of congenitally missing maxillary left lateral incisor. The interproximal space between tooth #21 and tooth #23 remained critical after orthodontic treatment.





**Fig. 3:** A 2.5 mm diameter hand reamer is used to expand the initial osteotomy previously prepared with the high-speed pilot drill. **Fig. 4:** The final 3 mm diameter hand reamer is carefully pressed by hand in between the two roots. The cutting edge is directed towards the palatal plate, and the rotation is a maximum of 45°. **Fig. 5:** The 3 mm diameter implant is inserted into the expanded osteotomy. Note the plateau design and the sloping shoulder at the neck. **Fig. 6:** The implants (Bicon Dental Implants) are inserted 2–3 mm under the crest. A 2 mm thin black PTFE healing post protected the implant during the healing period.

the horizontal bone formation inside the healing chambers guarantees blood supply to the adjacent periodontal ligament.<sup>14, 15</sup>

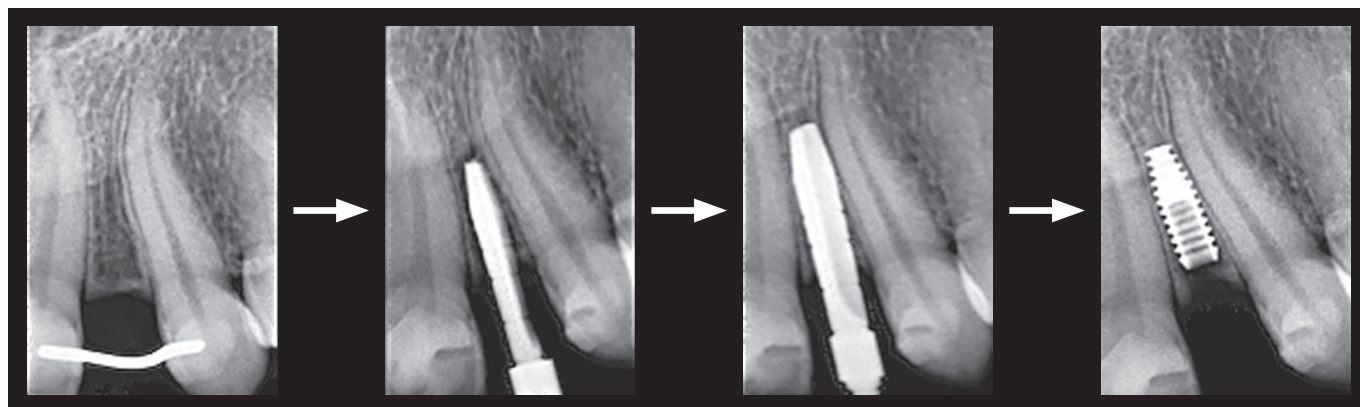
The sloping shoulder design combined with the sub-crestal placement of the plateau implant makes it possible for the restorative portion to respect all necessary parameters for a healthy crestal bone and its long-term preservation.<sup>16–18</sup> The implant neck in sub-crestal position (between 2 and 3 mm in the aesthetic area) respects the physical law that two objects cannot occupy the same space, which occurs with supra-crestal or transmucosal implant designs. In a reduced mesiodistal and buccoral space of approximately 4 mm, a 3.3 mm diameter implant would occupy almost all the crestal space, taking away the soft tissue's bony support.<sup>19</sup> However, the prosthetic shaft connection of a narrow sub-crestal implant is only 2 mm, allowing the crestal bone to regrow over the implant after its placement.<sup>20</sup> In our case, as in various other cases of congenitally missing maxillary anterior teeth, an interradicular space could not be achieved, and the space between the two adjacent roots was less than 4 mm (Fig. 1). Too close a drilling and the following insertion procedure of a conventional implant would have harmed the periodontal ligament.

## Case report

A 21-year-old healthy female patient presented complaining about a congenitally missing maxillary left incisor. She had undergone three years of orthodontic treatment, through which the orthodontist could only achieve a 4 mm mesiodistal space between the mesial contact point of the maxillary left canine and the distal contact point of the maxillary left central incisor. The periapical digital radiographic analysis showed that the distance between the roots after the first 6 mm from the crestal bone was only 2.7 mm, and after 8 mm, the interradicular space was only 2.1 mm (Fig. 2). We advised the patient

to undergo a second orthodontic treatment, but she refused, and we thus discussed inserting a narrow implant placed with the interproximal root spreading technique. The implant was 3 mm in diameter and 8 mm in length (Bicon Dental Implants) and had the following characteristics: press-fit implant tapped into the osteotomy; plateau root-form design without threads; sloping shoulder with reduced diameter at the neck (platform switching); sub-crestal placement 1–3 mm under the crestal bone. The patient was anaesthetised with articaine and epinephrine (Septocaine, Septodont), and a small crestal incision with a 15c blade was performed. The pilot drill was used at a speed of 1,100 rpm to perforate the cortical bone and to achieve a depth of approximately 4 mm. A 2.5 mm hand reamer and then a 3 mm diameter hand reamer were used for the root spreading.<sup>3, 4</sup>

The interproximal spreading technique entails gently pressing away the adjacent roots in a narrow interradicular space using a special instrument. The hand reamers (Bicon Dental Implants) have one vertical cutting edge ending in a sharp tip, and 270° of the reamer is a round non-cutting surface which acts as an expander. The hand reamers are pressed by hand into an initial osteotomy with the help of a threaded straight handle. This osteotomy is made with a regular 2 mm diameter pilot drill (1,100 rpm) and is only 3–4 mm deep. High-speed burs are traumatic in these cases because they could overheat the periodontal ligament and accidentally damage one of the roots. The initial 2 mm wide and 3–4 mm deep osteotomy is enough to allow the 2.5 mm diameter hand reamer to slide between the roots, keeping in mind that, firstly, the reamer tip is tapered 3 mm apically and therefore thinner than the diameter of the reamer body and, secondly, the cutting edge is used only to make its way along the thicker palatal plate. The round non-cutting surface of the reamer is pressed across the smooth cancellous bone and between the two roots without damaging them. This is possible because no torque or cutting is



**Fig. 7:** Radiographic follow-up of the interproximal root spreading technique. Note the 2.5mm and 3.0mm hand reamers sliding between the roots and making space for the 3.0mm diameter implant, which was placed 3.0mm under the crestal bone level.

involved during this procedure. The final 3mm diameter hand reamer was equally pressed into the osteotomy and directed between the roots. Continuous and slow pressure was applied on the straight handle. Sometimes the help of a mallet is needed to move the reamer 10–11mm down to the crest (Figs. 3 & 4).

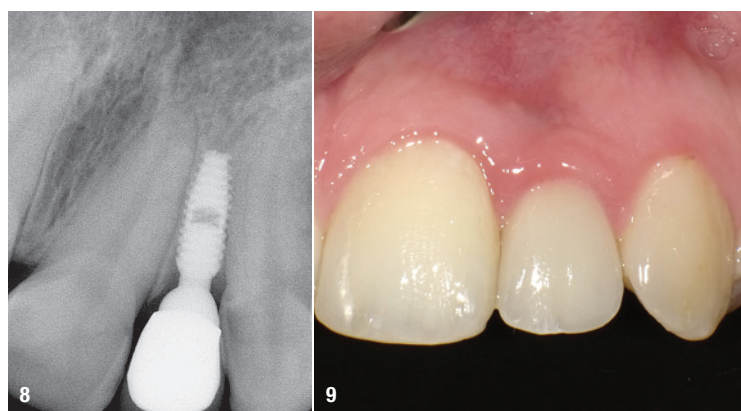
The implant was inserted with a special instrument (implant inserter), allowing the operator to push the implant with firm and precise pressure into the previously prepared osteotomy (Fig. 5). The last step was the final tapping with the mallet using the seating tip mounted on to the straight handle. The narrow implant was therefore compressed between the two roots (Fig. 6). The 3mm diameter and 8mm long implant was inserted with pressure into the finished osteotomy and tapped with the seating tip and the mallet 3mm down to the crestal bone (Fig. 7). After six months of healing, the second-stage procedure was performed and the implant well was exposed. An abutment with a 2mm diameter shaft and a 4mm diameter hemispherical base was selected to sup-

port the temporary crowns. It is paramount to let the soft tissue heal around the appropriate crown profile, and this aspect can be achieved by modifying the emergence profile of the temporary crown until the papillae are formed. Once the soft tissue had completely healed, the final impression was taken and the definitive crown cemented on to the titanium abutments (Figs. 8 & 9).

## Discussion

In the case of congenitally missing lateral incisors in the maxilla, planning of implant treatment depends on the following factors: condition of the neighbouring teeth, occlusion, space requirements and anterior relationships. There are several possible problems that need to be taken into consideration, such as close proximity of the apices of adjacent teeth to the proposed implant site, space limitations for implant placement and prosthodontic restoration, insufficient ridge thickness that requires augmentation and insufficient bone support for the gingival papillae.<sup>21</sup> Close proximity of the apices of neighbouring teeth often makes orthodontic treatment for angulation correction necessary. The adjacent roots should ideally be slightly divergent or parallel. A minimum of 1mm between the implant and the adjacent roots is recommended.<sup>10</sup> In our case, the spreading procedure had to be performed with both reamers (2.5 and 3.0mm) with a very slow motion. The pressing involves placing the palm of the hand on the straight handle wrench and at the same time rotating the handle less than 45° in order to engage the cutting tip in the cancellous bone. Once the reamer has been inserted into the bone to the desired depth, the reamer should be left inside the osteotomy for some minutes. That allows the bone and the ligament of the adjacent roots to adapt to the new positioning.<sup>23,24</sup>

No excessive pressure is exerted by the implant because no torque is used for the insertion. The special design of the implant (Bicon Dental Implants) with its



**Fig. 8:** Final radiographic control after three years of function. Note the platform switching between the neck of the implant and the hemispherical base of the abutment. **Fig. 9:** Intra-oral control of the crown and surrounding soft tissue at three years. Note the stability of the papillae, being supported by bone formed over the sloping shoulder.




plateaus and the interposed healing chambers, which are empty spaces between each plateau, result in minimally invasive compression against the surrounding areas.<sup>25</sup> In the 1980s, Ewers and Dueker published a study on beagles in which they inserted self-tapping osteosynthesis screws close to mandibular roots. The aim of the research was to observe with histology whether a tight compression of the periodontal ligament would lead to its damage or whether a repair reaction of the periodontal cell structure would lead to a positive result (Fig. 10). The histological results showed that compression on the periodontal ligament does not necessarily damage it, but instead produces a reaction by the connective cells.<sup>26,27</sup> The histology at root tip level showed the deviation of the periodontal ligament towards a new position (Fig. 11).

## Conclusion

The interproximal root spreading technique is a valid alternative to many bone grafting procedures if orthodontic treatment has not been able to move the interproximal roots of a congenitally missing maxillary anterior tooth. It is paramount to select the appropriate implant design and surgical technique in order to obtain a satisfactory surgical and aesthetic result.



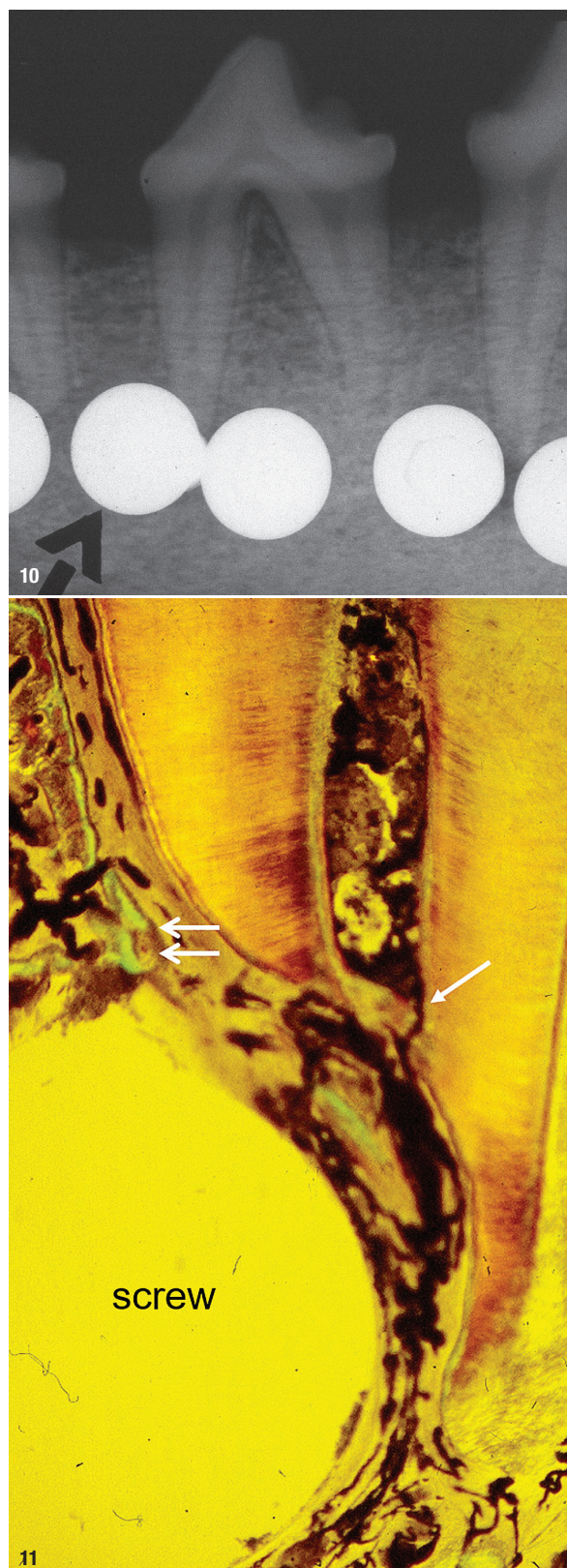
## about the author



A specialist in implant dentistry, **Dr Mauro Marincola** obtained his doctoral degree in dentistry in Rome in 1988. In 1990, he obtained the licence to practise dentistry in Germany. Dr Marincola completed a master's programme in stomatology with a focus on implantology in Rome in 1996. Since 1998, he has taught, as a Professor, oral implantology at the University of Cartagena in Colombia and he has been clinical co-director of the Implant Dentistry Centre in Boston in the US. In the same year, the Dental Association of Rhineland-Palatinate authorised him to be a Specialist for Implantology in Germany.

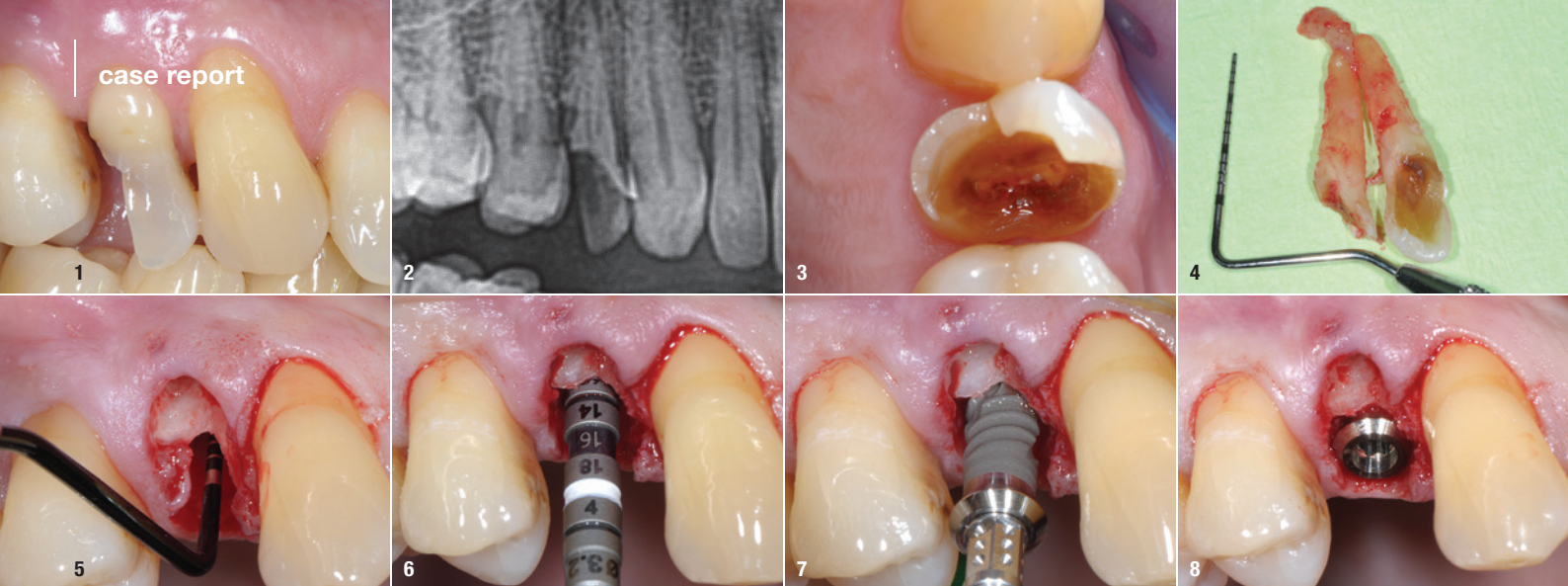
## contact

**Dr Mauro Marincola**  
Via dei Gracchi 285  
00192 Rome RM, Italy  
mmarincola@gmail.com



**Fig. 10:** Radiographic control of the teeth of an adult beagle dog after inserting several 2.5 mm thick Synthes screws into the mandible, trying to compress the roots as much as possible. **Fig. 11:** Undecalcified hard-tissue histological specimen. The area between the screw and the root tip was completely filled with connective tissue and had the appearance of new periodontal ligament.





**Fig. 1:** Frontal view, showing the fracture of the maxillary right first premolar. **Fig. 2:** Pre-op radiograph. **Fig. 3:** Occlusal view, showing caries into the root and involvement of the distal furcation. **Fig. 4:** The extracted tooth. **Fig. 5:** The socket was measured with a periodontal probe. **Figs. 6 & 7:** Insertion of the implant. **Fig. 8:** View of the implant immediately after insertion.

# Immediate **placement** of a new fully tapered tissue-level implant

Dr Mario Roccuazzo, Italy

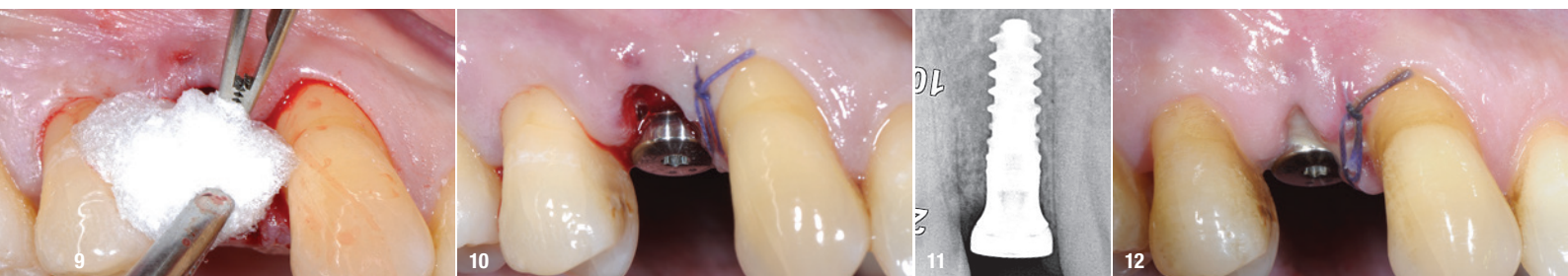
## Initial situation

In September 2019, a 53-year-old non-smoking male patient came for a consultation after the fracture of his maxillary right first premolar (Fig. 1). The patient presented with minimal periodontal problems, including multiple gingival recessions. The radiographic image confirmed the presence of a large periapical radiolucent area and some distal interproximal bone loss (Fig. 2). A thorough examination was carried out and revealed caries into the root and involvement of the distal furcation (Fig. 3). Upon clinical examination, the amount of healthy dentine was considered insufficient for a stump preparation for a conventional crown. Moreover, the patient was unwilling to undergo orthodontic

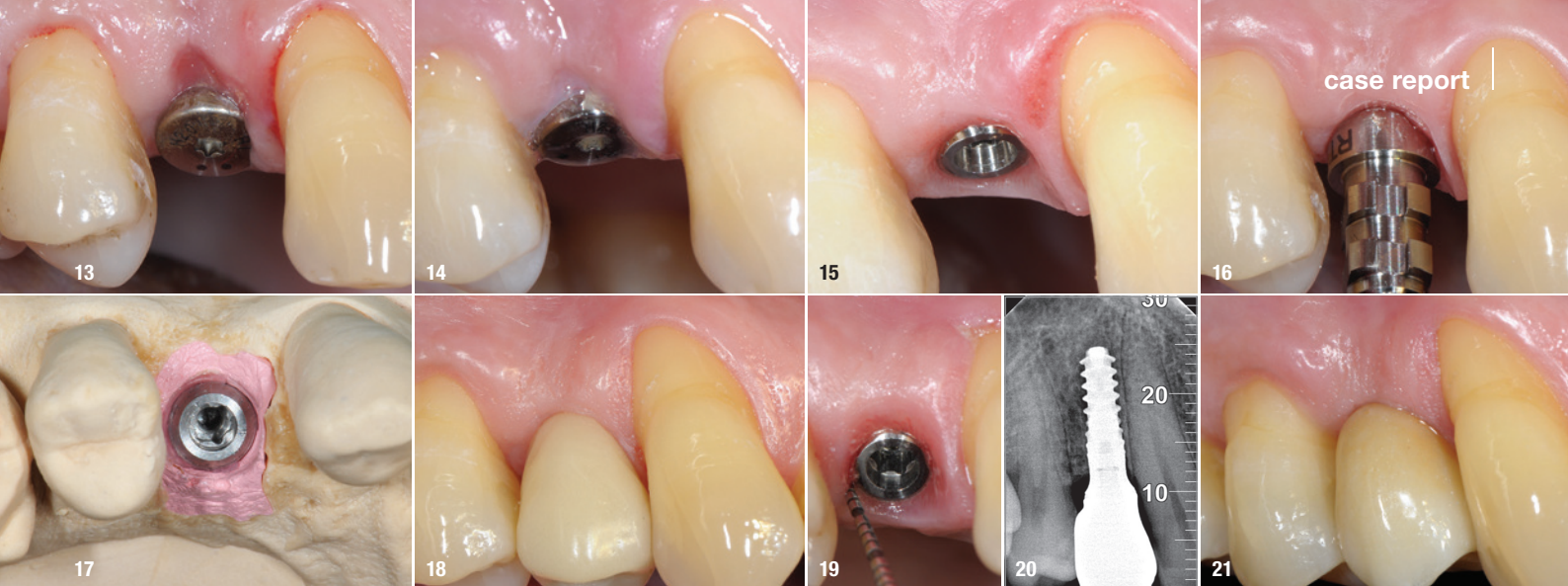
extrusion of the tooth. Additionally, an apically repositioned flap, after endodontic treatment, would have most likely produced a very long crown. Subsequent to the clinical evaluation, the patient gave his informed consent for the extraction of tooth #14 and immediate implant placement.

## Surgical procedure

In order to minimise the trauma during treatment, a careful separation of the tooth into two parts was carried out before extracting both roots (Fig. 4). No incisions were made, in order to reduce the risk of soft-tissue dehiscence. Before implant insertion, meticulous cleaning and careful curettage/debridement was carried out. The dimen-



**Fig. 9:** Placement of a flexible composite cone of synthetic and porcine origin. **Fig. 10:** Fixation of the mesial papilla with a suture. **Fig. 11:** Post-op radiograph. **Fig. 12:** Frontal view of the sutured implant site.



**Figs. 13 & 14:** Clinical situation at the follow-ups until one month after surgery. **Fig. 15:** Clinical situation six weeks after surgery. **Figs. 16–18:** An impression was taken, and a provisional crown was delivered. **Fig. 19:** Probing depths were checked before seating the definitive crown. **Fig. 20:** Radiographic evaluation in July 2020. **Fig. 21:** The final result.

sions of the socket were measured by means of a periodontal probe (Fig. 5). A TLX SP, RT, SLActive®, Roxolid® 3.75x12.00mm implant (Straumann Institut) was placed according to the manufacturer's instructions. The implant was inserted using the handpiece in a self-tapping fashion, and a high primary stability was achieved (Figs. 6 & 7). The implant was positioned according to the International Team for Implantology philosophy of "as shallow as possible, as deep as necessary", the SLActive® surface margin placed at bone level. The use of a reduced-diameter implant allowed the presence of more bone around the implant for greater long-term success. The implant was placed slightly on the palatal side of the alveolar bone crest, leaving sufficient space buccally (Fig. 8).

A flexible composite cone composed of synthetic granules and porcine collagen fibres (collacone® max, botiss biomaterials) was inserted into the buccal portion of the socket to reduce bone remodelling and possible soft-tissue recession (Fig. 9). The mesial papilla was fixed with a 4/0 Vicryl® suture (Fig. 10). The postoperative radiograph confirmed the good positioning of the implant in the vertical dimension (Fig. 11). The patient was instructed not to traumatise the area, to brush very carefully and to rinse with a 0.12% chlorhexidine digluconate solution for one minute three times a day for the same period. The suture was kept in place for one week (Fig. 12). The patient was seen once a week for the first month to monitor healing, which proceeded with no complications (Figs. 13 & 14). The patient was then instructed on proper brushing in order to have adequate plaque control without injuring the soft tissue.

## Prosthetic procedure

Six weeks after surgery, the peri-implant mucosa appeared to be free from inflammation and had an optimal contour (Fig. 15). After soft-tissue maturation, an impression was taken, and a provisional crown was delivered (Figs. 16–18). The provisional crown was kept in place for three months in order to facilitate soft-tissue maturation for

an ideal final aesthetic restoration. Before the delivery of the definitive metal–ceramic crown, the peri-implant soft tissue was checked with a probe, and the probing depths were found to be physiological (Fig. 19). The patient was asked to follow an individualised supportive periodontal therapy programme for an appropriate clinical and radiographic follow-up.

## Treatment outcomes

In July 2020, the radiographic examination confirmed the correct fitting of the crown on the implant and the good level of the interproximal bone crest (Fig. 20). Plaque control was adequate, the pocket depths were physiological and there was no bleeding on probing around the newly placed crown (Fig. 21).

*Acknowledgements: The author would like to thank Turin-based master dental technician Francesco Cataldi for carrying out the laboratory procedures.*

## about the author



**Dr Mario Rocuzzo** is a lecturer at the University of Turin in Italy and an adjunct clinical assistant professor at the University of Michigan School of Dentistry in Ann Arbor in the US. He maintains a private practice specialising in periodontics and implantology in Turin. Rocuzzo has been invited to lecture in 45 countries.

## contact

**Dr Mario Rocuzzo**  
Studio Dentistico Dr. Mario Rocuzzo  
Corso Alessandro Tassoni 14  
10143 Torino TO, Italy  
mroccuzzo@icloud.com



Author details



# Practice **strategies** in the time of the coronavirus

Dr Anna Maria Yiannikos, Cyprus

**We all have been experiencing** an extremely difficult period in the past few months. In the following, I would like to show you how you can utilise your social media channels more wisely and provide you with 5 important tips which will make the communication between you and your patients on social media during the current period even more effective. You will learn what to say and how to say it and attract new patients as a result—after all, we are not only dentists but also entrepreneurs with businesses to run.

## Tip 1: Seek to become closer to your patients

Use your social media channels to foster a closer relationship with your patients by giving them information on different useful topics during this difficult period. For instance, make short videos in which you explain to your patients how they can put on their protective face masks and remove them safely afterwards. The caption for such a video could be something along the lines of: “My beloved patients—friends—I would like you to know that it is totally normal to be unsure of whether you are properly following the advised safety measures, which have become an essential part of our everyday lives in these unprecedented times. To all of you, I wish good health and prosperity from the bottom of my heart.”

## Tip 2: Give advice on dental hygiene

Share important advice with your patients regarding their oral hygiene. Such advice should be based on their new routines in order to keep their mouths healthy. For instance, if your patients take vitamin C in order to boost their immune systems, you can give advice on which form would be the most suitable for their teeth. Or you could publish a post or a video on helping patients keep their teeth healthy during the pandemic.

## Tip 3: Offer online consultations

Give your patients the opportunity to conduct an online meeting with you. You could use the following script in a social media post in order to promote this service: “BECAUSE WE CARE—the health and safety of you, our

© Alessandro Biascioli — stock.adobe.com



precious patients, is our main concern. For this reason, we have a gift for you: we are offering online consultations to discuss any dental issue of concern to you. Additionally, if you desire an aesthetic transformation of your teeth, feel free to send us a private message with a photo of your teeth and a short description of how you would like your smile to be improved. We can schedule your online consultation via Viber, Messenger or WhatsApp [insert in your preferred platforms here]. We might be far from one another, but this can bring us closer together."

#### Tip 4: Promote a specific treatment that you offer

Use the current time to promote a certain treatment that you carry out in your practice, such as an Invisalign orthodontic treatment or a dental laser treatment. Promote these treatments by showcasing their distinctive advantages and the benefits that they have for your patients. Of course, patients are concerned that a lockdown might be put in place again in the regions where they live and many of them would love to learn more about a certain treatment that they would not necessarily undergo under normal circumstances for different reasons. The text for such a social media post could be as follows: "Why can the modern Invisalign orthodontic method be deemed SAFE and APPROPRIATE, especially during the pandemic? Let us explain. Firstly, during your orthodontic treatment with Invisalign, you do not have to go to dental appointments on a monthly basis. Secondly, if you run out of the aligners, which are usually changed every ten days, you can have the new ones sent to you via a courier service. Thirdly, with the Invisalign method, there are no emergencies! You don't need to worry that brackets or wires will become loose and come off, because in this orthodontic treatment method, there aren't any. Furthermore, the mouth guards used are almost invisible."

#### Tip 5: Demonstrate protective measures

Showcase all the protective measures that you are offering patients, using photographs and videos. I urge you not to see things from the standpoint of a dentist only, but to put yourselves in the shoes of your patients too. After many days in lockdown, being isolated and living with the fear of becoming infected with the coronavirus, would you not be relieved to know that the dental clinic you are visiting for treatment is putting protective measures and safety procedures in place that have enhanced health benefits for you as the patient? I would like to propose the following text for your social media post: "The health and safety of the patient comes FIRST! We are very cautious when it comes to your health, and therefore we have in place the following measures for YOUR safety: *[list all of these measures, including disposable face masks and their types, disposable protective hats, disposable surgical scrubs, disposable face shields, disposable den-*

*tal chair covers, disposable protective barriers (for the camera, LED operatory light, handles, radiographic devices), disposable carbon masks with valve, disposable shoe covers, automatic shoe cover dispenser and dental dams for tooth isolation and infection control]."*

Remember that, today, people are spending more time than ever on social media. This is your opportunity to attract many new patients and remind your already loyal patients that you are available and that you are there for them. Practice strategies in light of the coronavirus will also be the topic of my next article. Until then, consider that, in these uncertain times, patients will only invest their money in clinics they believe offer them high-value benefits. This is now true more than ever. Against this background, I would like to leave you with the following question: do you want to be the dentist that patients turn to in such unstable times as these?

If you have further questions or requests, whether you need information or guidance, feel free to reach out to me at [dba@yiannikosdental.com](mailto:dba@yiannikosdental.com).

#### about the author



**Dr Anna Maria Yiannikos** obtained her DDS from the National and Kapodistrian University of Athens in Greece in 1990, and she continued her education by completing a two-year Master of Science in Lasers in Dentistry at RWTH Aachen University in Germany, being one of the first two women worldwide to have obtained a master's degree in this field. She also holds an MBA from the Cyprus International Institute of Management. She has owned a dental clinic for more than three decades and leads the innovative Dental Business Administration Mastership Course at RWTH Aachen University. She is an adjunct faculty member of the Aachen Dental Laser Center and is a certified laser safety officer.

#### contact

##### Dr Anna Maria Yiannikos

Yiannikos Centre for Holistic Dentistry  
8 Alkeous & Pindarou Str  
1060 Nicosia  
Cyprus  
Phone: +357 22 764765  
[www.yiannikosdental.com](http://www.yiannikosdental.com)



bredent  
group



bredent medical

## Highest primary stability—now with conical-parallel connection

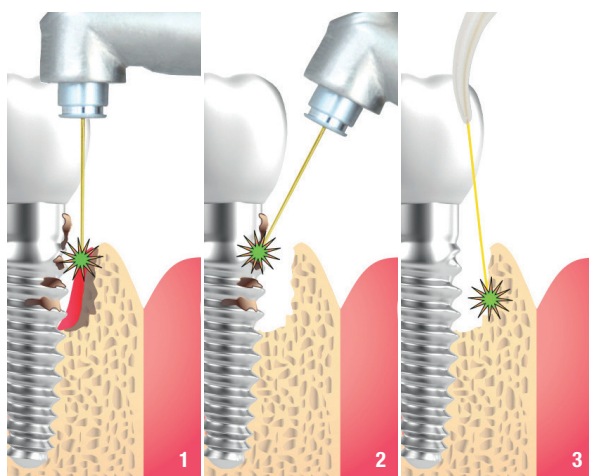
The new copaSKY implant line from bredent is particularly distinguished by the stable and retrievable conical-parallel-walled interface, which enables easy removal of the prosthetics. The unique neck design and short implant–abutment connection also allows ultrashort implants. Due to the deposition of bone chips on the backtaper, a subcrestal implant position can also be selected. copaSKY uses the same surgical tray as all other SKY implants. And the enhanced prosthetic offering one connection that fits all diameters of implants, simplifying storage and reducing inventory. The material of choice is BioHPP, which provides a natural chewing sensation and built-in shock absorber effect to

protect implants. Also new is the form-fit connection for bolted bridge components. The high accuracy of fit directs the lateral load directly onto the abutment, i.e. the risk of screw loosening and fractures is greatly reduced. The integrated angled screw channel provides excellent aesthetic results when transversally threaded.

**bredent medical GmbH & Co. KG**  
**Weißenhörner Straße 2**  
**89250 Senden, Germany**  
**[www.bredent-implants.com](http://www.bredent-implants.com)**

Fotona

## Peri-implantitis treatment with TwinLight



**Fig. 1:** Removal of the soft-granulation tissue and ablation of the infected bone with Er:YAG. **Fig. 2:** Removal of the bacterial biofilm on the implant surfaces with Er:YAG. **Fig. 3:** Bacterial reduction and biostimulation of the bone tissue with Nd:YAG.

Fotona's dual-wavelength LightWalker dental laser system is the ideal tool for effective minimally-invasive treatment of peri-implantitis. The system's TwinLight (Er:YAG and Nd:YAG) treatment option successfully addresses infection control, detoxification of implant surfaces, regeneration of lost tissues, and plaque-control regimens with no mechanical or chemical trauma, no danger of thermal damage to the surrounding bone and no significant alterations of the implant surface. First, the Er:YAG laser is used to remove microbial composition on the implant and to treat the damaged alveolar bone around the implant. Following Er:YAG treatment, the Nd:YAG laser wavelength is used for bacterial reduction and biostimulation. Inflammation, swelling, and bleeding of soft-tissue lesions, can be handled without surgery, and healthy peri-implant tissue assures greater long-term implant success.

**Fotona d.o.o.**  
**Stegne 7**  
**1000 Ljubljana, Slovenia**  
**[www.fotona.com](http://www.fotona.com)**



BioHorizons Camlog

## The next generation soft-tissue augmentation material



When choosing a biomaterial, there is a strong demand in clinical practice for predictable outcomes. For over 20 years, LifeCell, a leading global medical technology company, has developed innovative products for use in a wide range of applications. BioHorizons Camlog expands its soft-tissue portfolio to bring NovoMatrix, an innovative soft-tissue augmentation material. NovoMatrix is an acellular extracellular dermal matrix consisting of tissue-engineered porcine material. It is a breakthrough in xenogeneic processing ensuring a structurally intact, undamaged scaffold that supports cell and microvascular ingrowth. The proprietary tissue processing allows for rapid revascularisation, cell repopulation and minimal inflammation.

NovoMatrix comes pre-hydrated and ready to use and offers a true alternative to autogenous soft-tissue grafts and current products on the market. The NovoMatrix indications include guided tissue regeneration procedures in recession defects for root coverage, localised gingival augmentation to increase keratinised tissue (KT) around implants and natural teeth, and alveolar ridge reconstruction for prosthetic treatment.

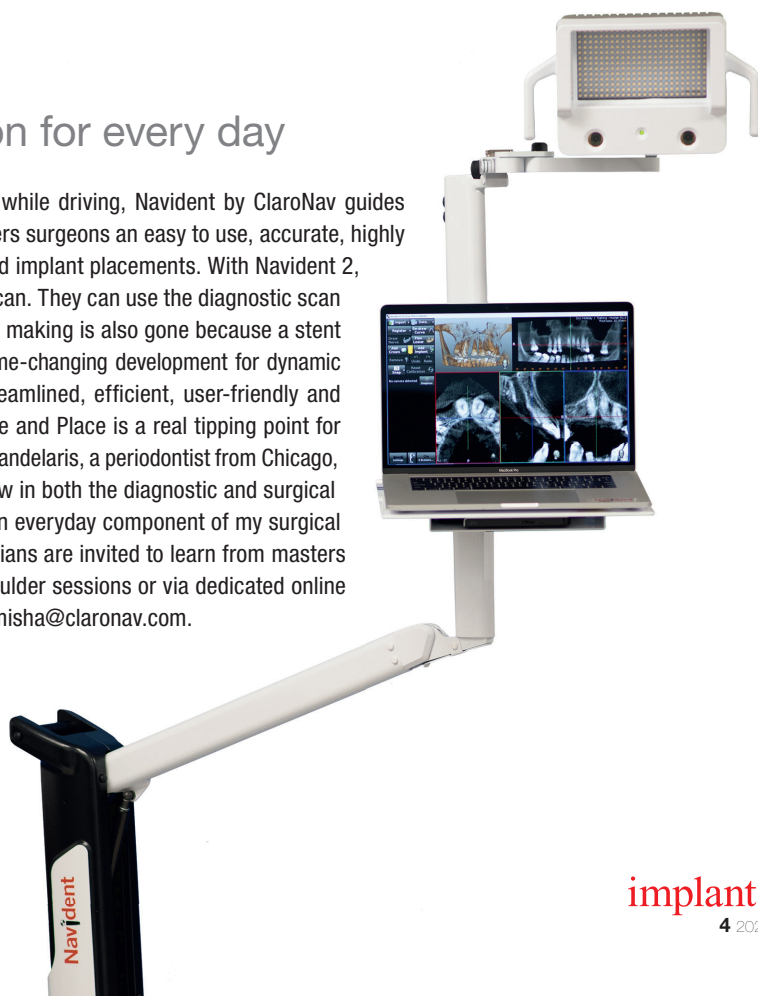**Camlog Biotechnologies GmbH**  
Margarethenstr. 38  
4053 Basel, Switzerland  
[www.biohorizonscamlog.com](http://www.biohorizonscamlog.com)

ClaroNav

## State-of-the-art navigation for every day

Similar to the way that a GPS system guides you while driving, Navident by ClaroNav guides clinicians by using the CBCT image as a map. It offers surgeons an easy to use, accurate, highly portable and affordable way to plan restorations and implant placements. With Navident 2, clinicians will no longer need to do a special extra scan. They can use the diagnostic scan already available for the patient. The stress of stent making is also gone because a stent is no longer required. Trace and Place (TaP) is a game-changing development for dynamic navigation. With TaP, the Navident workflow is streamlined, efficient, user-friendly and seamlessly integrated into the daily practice. "Trace and Place is a real tipping point for dynamic navigation guidance," said user Dr George Mandelaris, a periodontist from Chicago, USA. "It has streamlined and simplified the workflow in both the diagnostic and surgical phases to allow state-of-the-art technology to be an everyday component of my surgical implant practice. I can't imagine going back." Clinicians are invited to learn from masters and interact with peers during regular over-the-shoulder sessions or via dedicated online meetings. For more information, please contact [kemisha@claronav.com](mailto:kemisha@claronav.com).

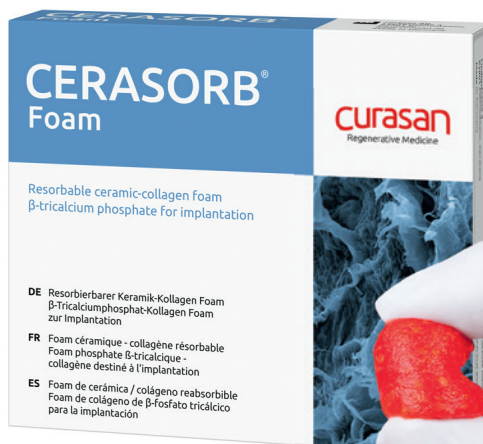**ClaroNav Inc.**  
1140 Sheppard Avenue West, Unit 10  
M3K 2A2 Toronto, Canada  
[www.claronav.com](http://www.claronav.com)



curasan

## Complete bone regeneration with CERASORB® Foam


CERASORB® Foam is a multi-porous composite material made from collagen and pure-phase  $\beta$ -TCP granules of different sizes and densities. The granules are embedded in the collagen component and are fixed by its fibres. CERASORB® Foam has particularly user-friendly properties. Moistened with blood from the defect or mixed with autologous thrombocyte and fibrin concentrate, the material can be modelled and inserted into the defect precisely and comfortably. The large contact area with the surrounding vital bone allows bone-forming cells to tap into the material and also facilitates the absorption of nutrients and proteins. In addition, CERASORB® Foam is an ideal scaffold for various antibiotics. The special CERASORB® collagen matrix ensures a high level of volume stability after the collagen, which is more rapidly absorbed, has broken down. The high porosity of the granulate, in turn, offers the newly forming bone a stable framework. CERASORB® Foam is completely broken down and replaced by autologous, healthy bone. Over 200 publications prove its success (a list of literature can be provided by curasan upon request).



**curasan AG**  
**Lindigstraße 4**  
**63801 Kleinostheim, Germany**  
**[www.curasan.de](http://www.curasan.de)**

PreXion

## Special autumn deal for CBCT system



The Japanese CBCT specialist PreXion offers customers based in Germany, Austria and Switzerland a special autumn deal. The special price for the PreXion3D EXPLORER includes the CBCT system, installation, instruction, five-year warranty, and a computer running the PreXion Viewer Software. Additionally, customers can opt for the attractive package including the pre-installed SICAT Suite and receive a special discount (66 per cent on the subscription price). With a focal point of 0.3 mm and a voxel size of just 74  $\mu$ m, the PreXion3D EXPLORER brings an extraordinary combination of great image detail and low radiation exposure to dental practices and clinics. Another highlight is the integrated cephalometric "One-Shot" mode, which allows the work in limited spaces. Interested ones are warmly invited to live demonstrations of the PreXion3D EXPLORER at the PreXion showroom in Rüsselsheim in Germany. Appointments can be made online at [www.prexion.eu](http://www.prexion.eu), via e-mail at [info@prexion-eu.de](mailto:info@prexion-eu.de) or by phone under +49 6142 407855.

**PreXion (Europe) GmbH**  
**Stahlstraße 42**  
**65428 Rüsselsheim, Germany**  
**[www.prexion.eu](http://www.prexion.eu)**



## Dentsply Sirona

### Versatility in implant dentistry with Astra Tech Implant EV



Dentsply Sirona continues to deliver innovation, versatility and clinical benefits in implant dentistry, based on the needs of customers and centred around well-documented and clinically proven implant systems. With the latest product development, the Astra Tech Implant System—one of the most well-documented implant systems in the market today, documented in over 1,000 publications in peer-reviewed journals—

just got even better: Astra Tech Implant EV has a revised implant design change that comes with significant advantages—with a deeper implant thread design apically, it is easier to reach preferred primary stability and the handling experience is enhanced for easy installation. With this new change

in design properties also comes the new name—

Astra Tech Implant EV. Dentsply Sirona continually strives to increase the application of implant therapy, based on science and without compromising safety and efficacy.

**Dentsply Sirona**  
Aminogatan 1  
41321 Mölndal, Sweden  
[www.dentsplysirona.com/implants](http://www.dentsplysirona.com/implants)

## Bicon

### More than just an alternative to sinus lift and augmentation

The plateau design, which has been clinically proven for 35 years, and the self-locking tapered implant–abutment connection are the most important success factors of the popular Bicon SHORT Implant™ system. While screw implants can cause bone loss under unfavourable conditions, experts associate the so-called “plateau anchors” with possible bone gain. The plateau design, which offers at least 30 per cent more bone surface than comparable screw implants, makes all the difference. Studies indicate that the unique Bicon design favours the formation of mature lamellar Haversian bone. In addition, the biomechanical advantages of the plateaus optimise lateral force distribution, which supports bone preservation. The self-locking, bacteria-proof connection and the integrated platform-switching additionally promote the long-term success of the system in terms of function and aesthetics. With implant lengths of 5, 6, 8, and 11 mm, Bicon serves the entire range of indications in daily implant dentistry.




**Bicon**  
501 Arborway  
Boston, MA 02130, USA  
[www.bicon.com](http://www.bicon.com)

## Straumann

### Iconic tissue level meets immediacy

Straumann has built on and perfected its well established Straumann® TL system to take the science of tissue-level implants to the next level. The Straumann® TLX system combines a neck design mimicking the natural anatomy and respecting the biological distance in all dimensions with Straumann's latest innovative endosteal design, optimised for primary stability.

**Institut Straumann AG**  
Peter Merian-Weg 12  
4000 Basel, Switzerland  
[www.straumann.com](http://www.straumann.com)



#### The Straumann® TLX System:

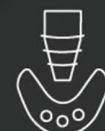- significantly reduces the risk of inflammation and bone resorption, thanks to the prosthetic margin at tissue level and the microgap respecting the biological distance in all dimensions.
- makes immediate protocols achievable and minimally invasive in all bone types in the most demanding clinical situations.
- allows clinicians to increase efficiency with a one-stage, straightforward workflow.
- forms the perfect complement to the Straumann® BLX system for bone-level implants. Both systems use one common drill set and TorcFit™ connection for maximum compatibility with minimum investment.

Coming 2<sup>nd</sup> half of 2021



# DENTSPLY SIRONA WORLD 2020

THE ULTIMATE DENTAL MEETING  
FOR HEALTHY PRACTICES & HEALTHY SMILES



Implantology

Focus on implant dentistry at

## This year's Dentsply Sirona World

From 14 to 20 November 2020, Dentsply Sirona World was held virtually. The event offered participants the unique opportunity to dive into more than 70 lectures out of twelve education tracks including digital dentistry, imaging, orthodontics, dental hygiene, restorative dentistry, and endodontics. More than 65 speakers shared their industry advice and expertise in a multi-discipline panel of educational options. A special focus this year was on implantology with a myriad of lectures that covered virtually every aspect of this special discipline within dentistry. For instance, in a session titled "Azento Workflow with Immediate Implant Placement", Dr Doug Smail showed the entire process from tooth extraction to immediate implant insertion and temporisation in less than an hour. Dr Fahrad Botchi, on the other hand, spoke about digital implant dentistry strategies that can aid in treating hopeless teeth in the aesthetic zone. He presented a clinical case in which CEREC technology in combination with an Astra Tech Implant

System was used to treat an anterior tooth gap. Botchi argued that, by adding a connective tissue graft at the time of immediate implant placement, postoperative recession can be reversed and tissue can be gained. Apart from that, the advanced CEREC trainer Dr Dan Buttermann discussed a truly crown down approach to implant dentistry by means of CEREC and CBCT integration. In his online session, he performed a guided implant placement and evaluated custom healing abutment and temporary options in about thirty minutes. The aim was to compare and contrast CEREC Guide 3 and Azento implant solutions. Those who weren't able to participate in this year's virtual mega event can already look forward to 23 September 2021, when the Ultimate Dental Meeting will kick off again in Las Vegas, USA. More information can be found on [www.dentsplysirona.com/en-us/ds-world.html](http://www.dentsplysirona.com/en-us/ds-world.html).

Source: Dentsply Sirona

TBR Dental acquisition opens

## New perspectives in Spain

Driven by the development of the Z1 Tissue Level implant and the Index digital workflow, TBR Dental integrates SAS Exclusivas Dentales, S.L. into its group and consolidates its long-term presence in Spain. Based in Valencia and with more than 30 years of experience in the Spanish market, SAS Exclusivas Dentales supports dental professionals in their search for technical excellence through a practical and local approach. The company's portfolio offers specialised and innovative products with a perfect knowledge of the needs of the dental community. "We are pleased to welcome Sally Bustos and Sergio Aldazosa, directors of SAS Exclusivas Dentales, to the TBR Dental Group. Their involvement, their experience and the dynamism of their talented team have enabled SAS Exclusivas Dentales to become an important player in the Spanish dental market", explains



**TBR**

**EXCLUSIVAS  
DENTALES, S.L.**  
S.A.S.

Julien Benhamou, CEO of TBR Dental. Today, TBR Dental and SAS Exclusivas Dentales are pushing forward the deployment of unique and exclusive products in a Spanish market that is as dynamic as ever.

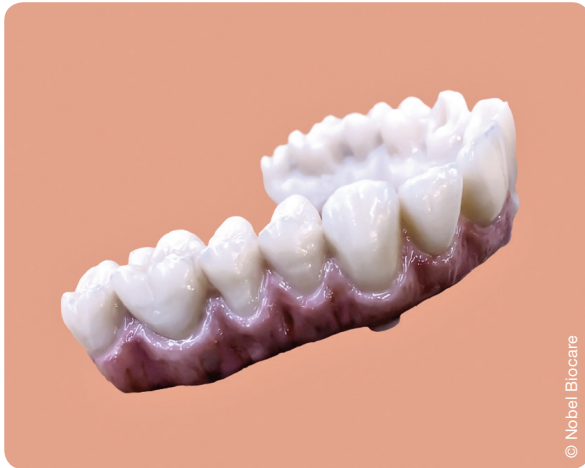Source: TBR Dental Group



## Nobel Biocare and DOCERAM Medical Ceramics

### Announce expanded partnership

Nobel Biocare and DOCERAM Medical Ceramics are combining their strengths to offer more high-quality restorative solutions, and with ease and flexibility for customers in mind. The first achievement in this strengthened partnership is the release of the



NobelProcera® next generation Zirconia implant bridge, from 2–14 units in various design options, including full contour.

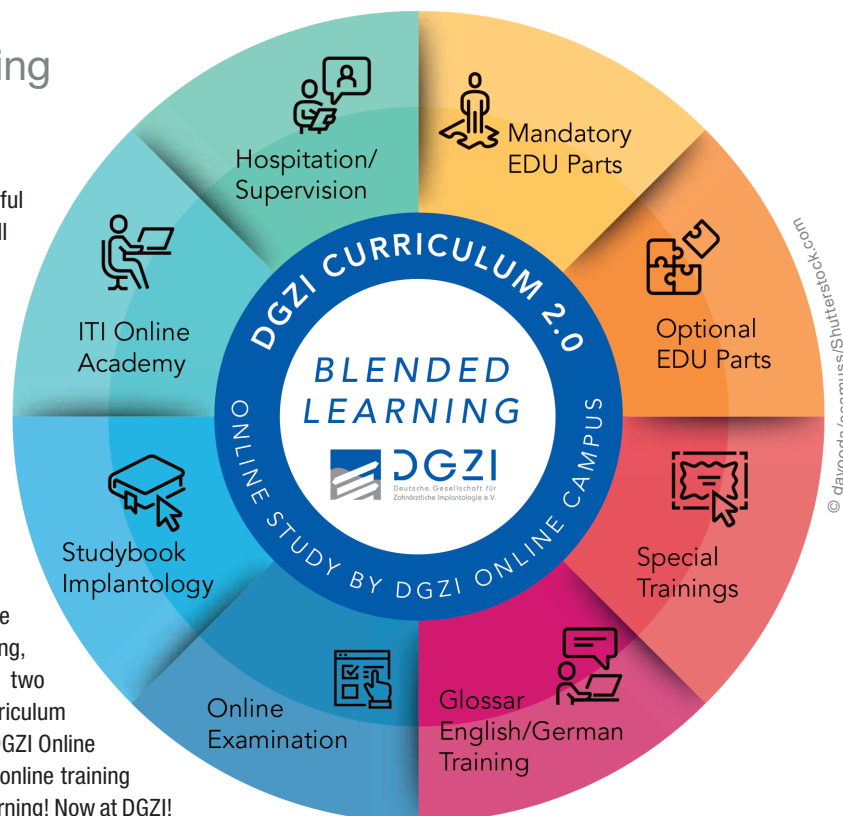
NobelProcera® Zirconia Implant Bridge, which enables restorative flexibility through a simplified workflow and is produced with the high-end Nacera® Pearl zirconia material. The two dental specialists have already been cooperating for many years in research, development and production. The crucial factor for both parties throughout has always been the exceptionally high standard of quality and reliability of the products as well as the associated customer satisfaction. Going forward, the aim is to further enhance this successful cooperation strategically. The even closer cooperation between the two companies creates synergies for mutual advancement, including technical training and customer service. For more than 20 years, DOCERAM Medical Ceramics has used its technical expertise to engage in the development and manufacture of zirconium oxide components for dental technology. The Nacera® brand and Nacera® Pearl series offer dental technicians a zirconium oxide material combining high bending strength and optimum aesthetics. High-quality Nacera® process-optimisation products, and other accessories for finalising full monolithic restorations, are also supplied so that zirconium processing can be completed in the laboratory.

**Source: Nobel Biocare**

## DGZI Online Campus

### International online training wherever you are

The structure and content of DGZI's successful implantology curriculum was revised in 2019. All participants now have access to the ITI Academy, where young dentists with little experience in implantology can learn the basics of implant dentistry. All participants in the curriculum will start their training in the new "DGZI Online Campus". This has been completely redesigned and enables e-learning from all devices and from anywhere you have online access. The theoretical basics of implant dentistry are well presented and taught in separate modules. Each module ends with a learning success check, which can be practised as often as required in advance in test examinations. After successful online training, three practice-related compulsory modules and two therapy-related optional modules follow. The curriculum is supported by special learning materials of the DGZI Online Campus. Start with the new concept of the DGZI online training at home or wherever you are—that is Blended Learning! Now at DGZI!



**Contact:** sekretariat@dgzi-info.de; info.vollmer@t-online.de

# Congresses, courses and symposia



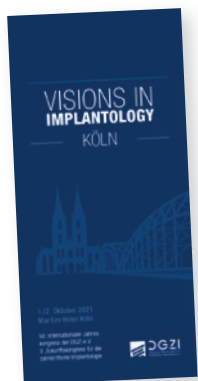## IDS Cologne

10–13 March 2021  
Cologne, Germany  
[www.ids-cologne.de](http://www.ids-cologne.de)



## 6th Annual Meeting of ISMI

7–8 May 2021  
Düsseldorf, Germany  
[www.ismi-meeting.com](http://www.ismi-meeting.com)



## 50th DGZI International Annual Congress— Visions in Implantology

1–2 October 2021  
Cologne, Germany  
[www.dgzi-jahreskongress.de](http://www.dgzi-jahreskongress.de)



## 30th annual scientific meeting of EAO

14–16 October 2021  
Milan, Italy  
[www.eao.org](http://www.eao.org)

# implants

international magazine of oral implantology

## Imprint

### Publisher

Torsten R. Oemus  
[oemus@oemus-media.de](mailto:oemus@oemus-media.de)

### CEO

Ingolf Döbbecke  
[doebbecke@oemus-media.de](mailto:doebbecke@oemus-media.de)

### Members of the Board

Jürgen Isbaner  
[isbaner@oemus-media.de](mailto:isbaner@oemus-media.de)

Lutz V. Hiller  
[hiller@oemus-media.de](mailto:hiller@oemus-media.de)

### Chief Editorial Manager

Dr Torsten Hartmann  
(V. i. S. d. P.)  
[hartmann@dentalnet.de](mailto:hartmann@dentalnet.de)

### Editorial Council

Dr Rolf Vollmer  
[info.vollmer@t-online.de](mailto:info.vollmer@t-online.de)

Dr Georg Bach  
[doc.bach@t-online.de](mailto:doc.bach@t-online.de)

Dr Suheil Boutros  
[SBoutros@aol.com](mailto:SBoutros@aol.com)

### Editorial Office

Georg Isbaner  
[g.isbaner@oemus-media.de](mailto:g.isbaner@oemus-media.de)

Johannes Liebsch  
[j.liebsch@oemus-media.de](mailto:j.liebsch@oemus-media.de)

### Executive Producer

Gernot Meyer  
[meyer@oemus-media.de](mailto:meyer@oemus-media.de)

### Product Manager

Timo Krause  
[t.krause@oemus-media.de](mailto:t.krause@oemus-media.de)

### Art Director

Alexander Jahn  
[a.jahn@oemus-media.de](mailto:a.jahn@oemus-media.de)

### Designer

Sandra Ehnert  
[s.ehnert@oemus-media.de](mailto:s.ehnert@oemus-media.de)

### Customer Service

Marius Mezger  
[m.mezger@oemus-media.de](mailto:m.mezger@oemus-media.de)

### Published by

OEMUS MEDIA AG  
Holbeinstraße 29  
04229 Leipzig, Germany  
Tel.: +49 341 48474-0  
Fax: +49 341 48474-290  
[kontakt@oemus-media.de](mailto:kontakt@oemus-media.de)

### Printed by

Silber Druck oHG  
Otto-Hahn-Straße 25  
34253 Lohfelden, Germany

### implants

international magazine of oral  
implantology is published in cooperation  
with the German Association of Dental  
Implantology (DGZI).

### DGZI

DGZI Central Office  
Paulusstraße 1  
40237 Düsseldorf, Germany  
Tel.: +49 211 16970-77  
Fax: +49 211 16970-66  
[office@dgzi-info.de](mailto:office@dgzi-info.de)

[www.dgzi.de](http://www.dgzi.de)

[www.oemus.com](http://www.oemus.com)

[www.implants.de](http://www.implants.de)



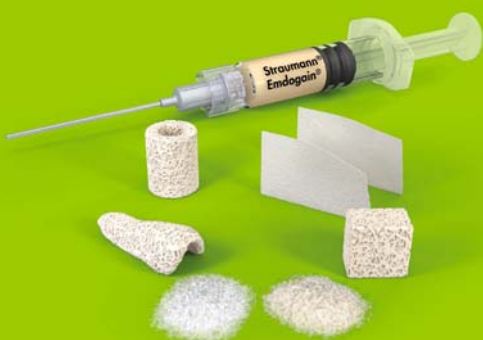## Copyright Regulations

**implants international magazine of oral implantology** is published by OEMUS MEDIA AG and will appear with one issue every quarter in 2020. The magazine and all articles and illustrations therein are protected by copyright. Any utilisation without the prior consent of editor and publisher is inadmissible and liable to prosecution. This applies in particular to duplicate copies, translations, microfilms, and storage and processing in electronic systems.

Reproductions, including extracts, may only be made with the permission of the publisher. Given no statement to the contrary, any submissions to the editorial department are understood to be in agreement with a full or partial publishing of said submission. The editorial department reserves the right to check all submitted articles for formal errors and factual authority, and to make amendments if necessary. No responsibility shall be taken for unsolicited books and manuscripts. Articles bearing symbols other than that of the editorial department, or which are distinguished by the name of the author, represent the opinion of the aforementioned, and do not have to comply with the views of OEMUS MEDIA AG. Responsibility for such articles shall be borne by the author. Responsibility for advertisements and other specially labeled items shall not be borne by the editorial department. Likewise, no responsibility shall be assumed for information published about associations, companies and commercial markets. All cases of consequential liability arising from inaccurate or faulty representation are excluded. General terms and conditions apply, legal venue is Leipzig, Germany.



## Straumann® Biomaterials Master any challenge.



### COMPREHENSIVE

Comprehensive and complete portfolio to master your challenges in periodontal regeneration.



### INDIVIDUAL SOLUTIONS

Innovative, tailored solutions for the challenges you face.



### POWERFUL

Powerful products backed by scientific evidence to meet your daily challenges.




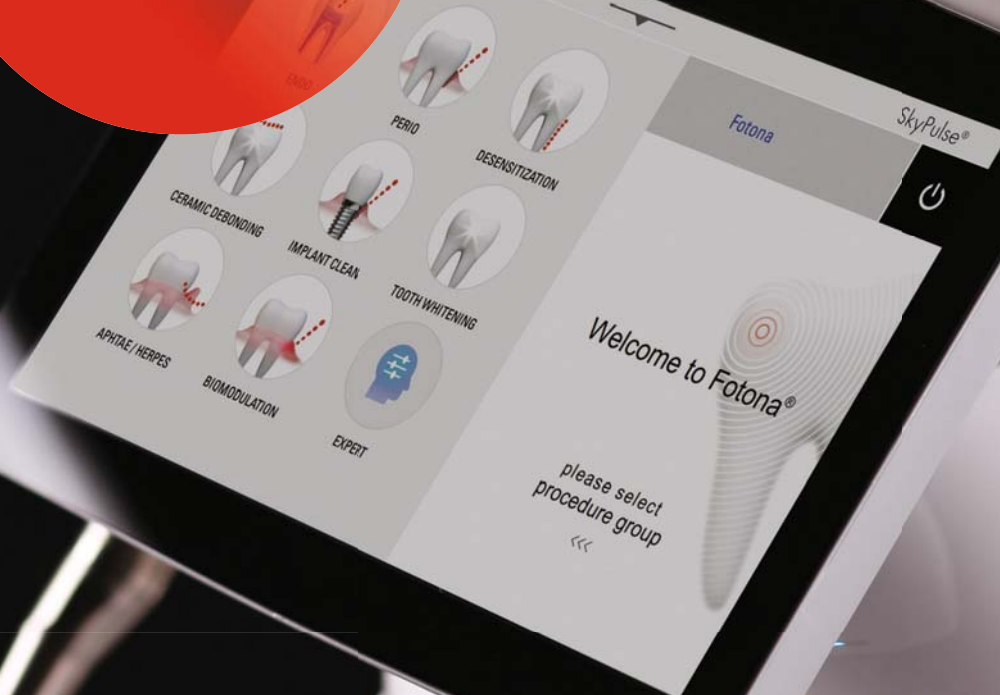
Contact your local Straumann representative now or visit [www.straumann.com/biomaterials](http://www.straumann.com/biomaterials)

A0008/en/C/00 02/20

# SkyPulse®

A new generation of compact  
Fotona lasers

A compact, easy  
to use Er:YAG Laser  
tailored for Your  
practice!



Committed to Engineering

The Highest Performance, Best Made Laser Systems in the World

Fotona®  
choose perfection

[www.fotona.com](http://www.fotona.com)